

[illegible]

1

7

8

9

10

11

12

13

14

15

16

17

18

19

20

21

22

23

24

25

26

27

28

29

30

31

32

33

34

35

36

37

38

39

40

41

42

43

44

45

46

47

48

49

50

51

52

53

54

55

56

57

58

59

60

61

62

63

64

65

66

67

68

69

70

71

72

73

74

75

76

77

78

79

80

81

82

83

84

85

86

87

88

89

90

91

92

93

94

95

96

97

98

99

100

101

102

103

104

105

106

107

108

109

110

111

112

113

114

115

116

117

118

119

120

121

122

123

124

125

126

127

128

129

130

131

132

133

134

135

136

137

138

139

140

141

142

143

144

145

146

147

148

149

150

151

152

153

154

155

156

157

158

159

160

161

162

163

164

165

166

167

168

169

170

171

172

173

174

175

176

177

178

179

180

181

182

183

184

185

186

187

188

189

190

191

192

193

194

195

196

197

198

199

200

201

202

203

204

205

206

207

208

209

210

211

212

213

214

215

216

217

218

219

220

221

222

223

224

225

226

227

228

229

230

231

232

233

234

235

236

237

238

239

240

241

242

243

244

245

246

247

248

249

250

251

252

253

254

255

256

257

258

259

260

261

262

263

264

265

266

267

268

269

270

271

272

273

274

275

276

277

278

279

280

281

282

283

284

285

286

287

288

289

290

291

292

293

294

295

296

297

298

299

300

301

302

303

304

305

306

307

308

309

310

311

312

313

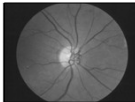
314

2

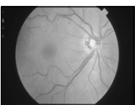
[illegible]

Optic Nerve Shunts and Collaterals

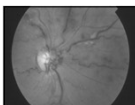
- Branching at the ganglion to converge and fill out the lamina propria axons
- Intraneural microvascular abnormalities
- Abnormal optic disc vasculature
- Choroidal Glaucoma
- High and increased intraocular pressure in glaucoma



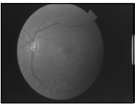
1A



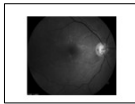
1B



1C

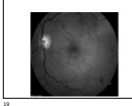


1D



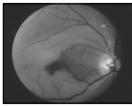
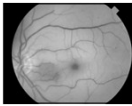
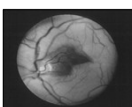
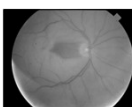
1E

3

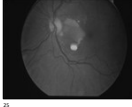


Cilioretinal Arteries

- Not a derivative of central retinal artery
- Branch from branch artery in the posterior ciliary system
- Branch from the temporal edge of the disc
- Arteries only
- Supply the inner retina inside the pigmented band (RNFL + ONL)
- Can become occluded causing central defect

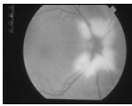
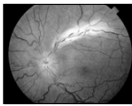
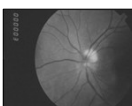






4

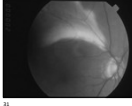


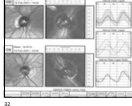
Myelinated Nerve Fiber


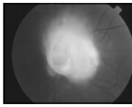
- 1% of population, asymptomatic
- Can cause central scotoma
- Consideration in differential diagnosis of the patient
- Not a retinal degenerative condition - manifestation of underlying pathology
- Benign - peripheral field defect from myelinated fiber
- More difficult when from optic nerve atrophy

5





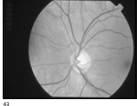
Parapapillary Atrophy

- Seen more in PVD, Alpha and beta
- Affects the inner retina
- Seen in the inner retina
- Benign condition

Parapapillary Atrophy

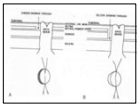
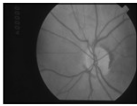
- Alpha more present in distant all normal eyes
- Beta more present in the inner retina
- A large beta area or progressive enlargement of the beta area can signal progressive atrophy
- More extensive than alpha

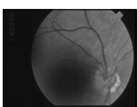
6



Optic Nerve Crescents

- Characteristic Crescent
- White crescent
- Can be seen adjacent to optic disc (OR)
- Can be seen adjacent to optic disc (OR)
- Can be seen adjacent to optic disc (OR)
- Can be seen adjacent to optic disc (OR)
- Can be seen adjacent to optic disc (OR)

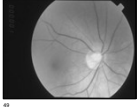




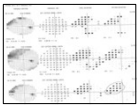
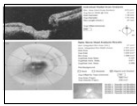




Inferior Scleral Crescent Syndrome

- Also known as Scleritis
- Characterized by hyperplastic tissue that is vertically oriented
- Can be seen adjacent to optic disc (OR)
- Can be seen adjacent to optic disc (OR)
- Can be seen adjacent to optic disc (OR)
- Can be seen adjacent to optic disc (OR)
- Can be seen adjacent to optic disc (OR)

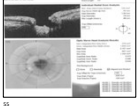
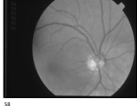
7

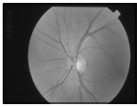
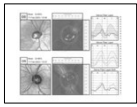



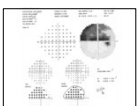
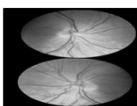



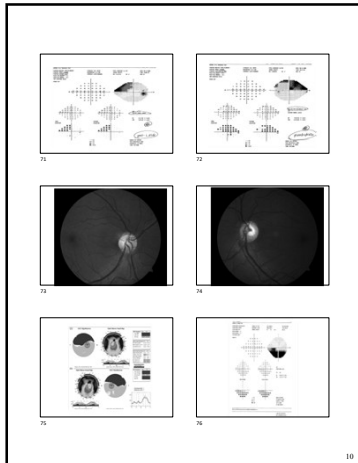
8

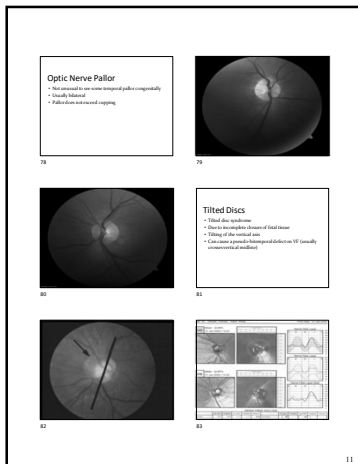



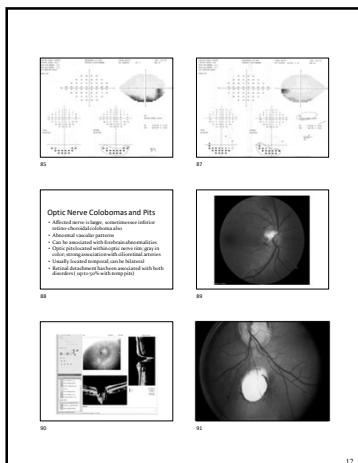
9



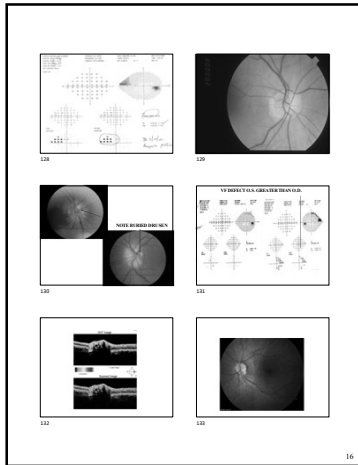
10



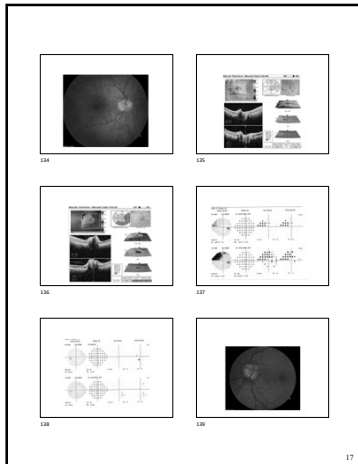
11




12



16



17



18

[illegible]

19

[illegible]

20

[illegible]

21

22

23

24

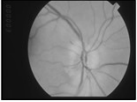
28

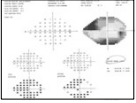
29


30

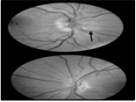
Diabetic Optic Neuropathy

- Diffuse peripapillary greyish discoloration (RN)
- Diffuse or focal retinal lesions
- Can occur in the early, silent or in EDMA
- Usually resolves after 1000mg prednisone
- Monitor clinical improvement and ERG (slowly)
- To avoid steroid-induced glaucoma









Learning Objectives:

- To be able to differentiate congenital from acquired optic nerve disease
- To explain which diseases cause congenital optic nerve degeneration (e.g. Leber's Hereditary Optic Neuropathy)
- To be able to identify optic disc appearance leading to differentiating congenital from acquired optic nerve disease

31

11