



Radiology Quiz

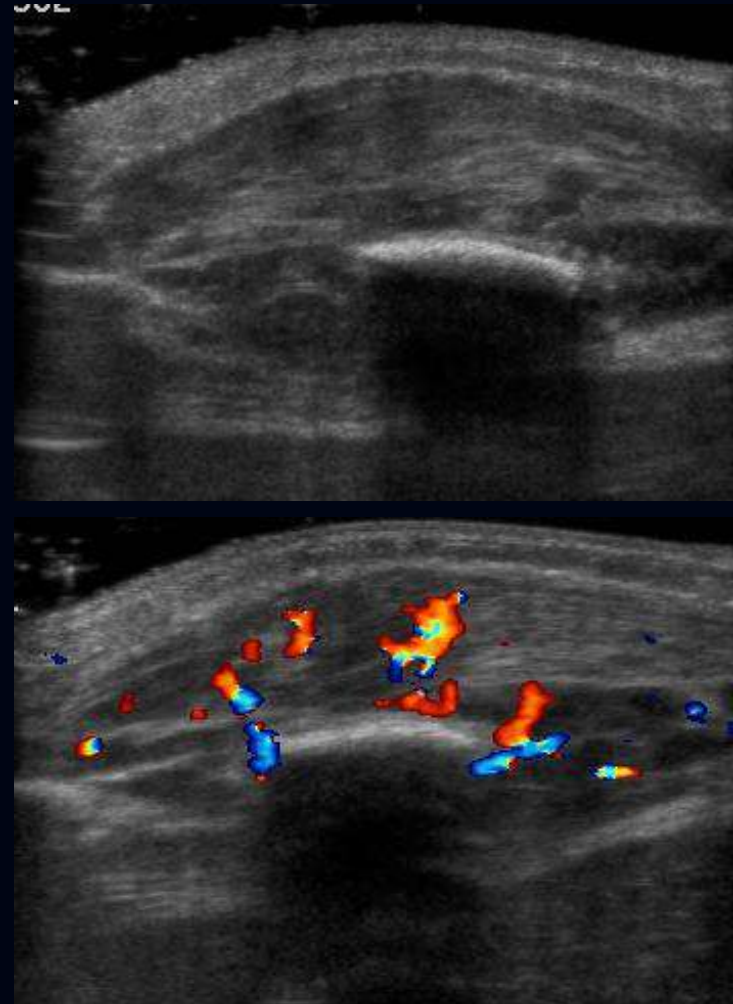
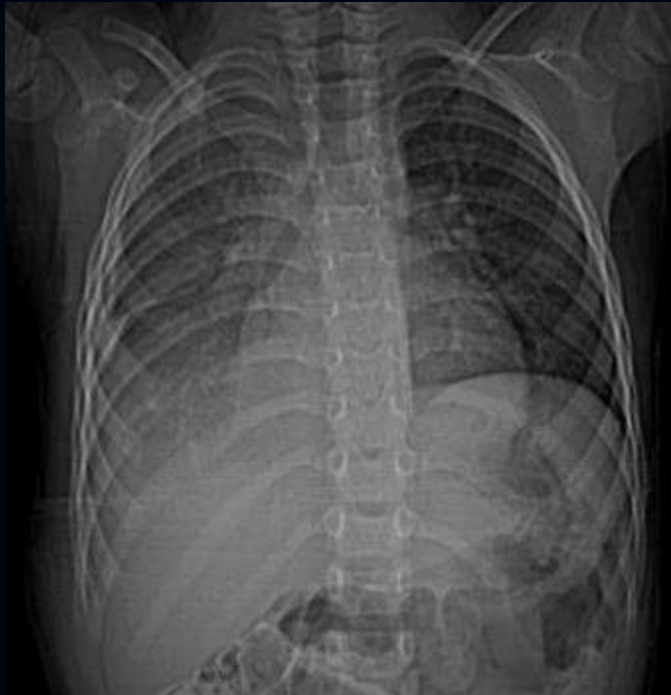R. Paul Guillerman, MD

Professor of Radiology, Department of Radiology
Cincinnati Children's Hospital Medical Center
Cincinnati, Ohio

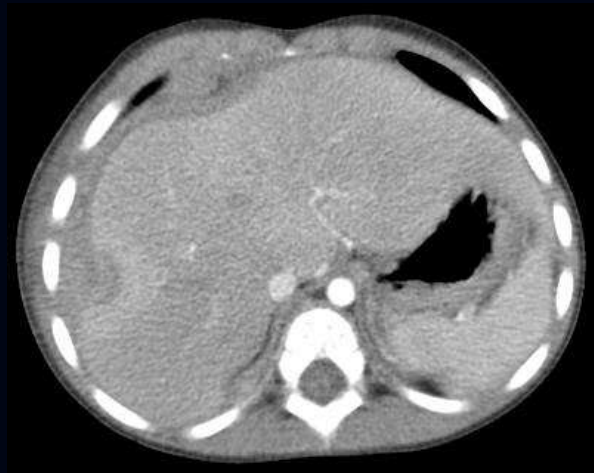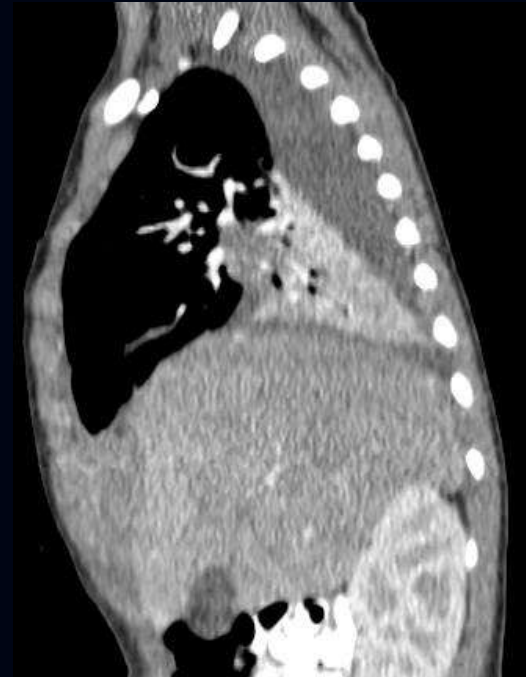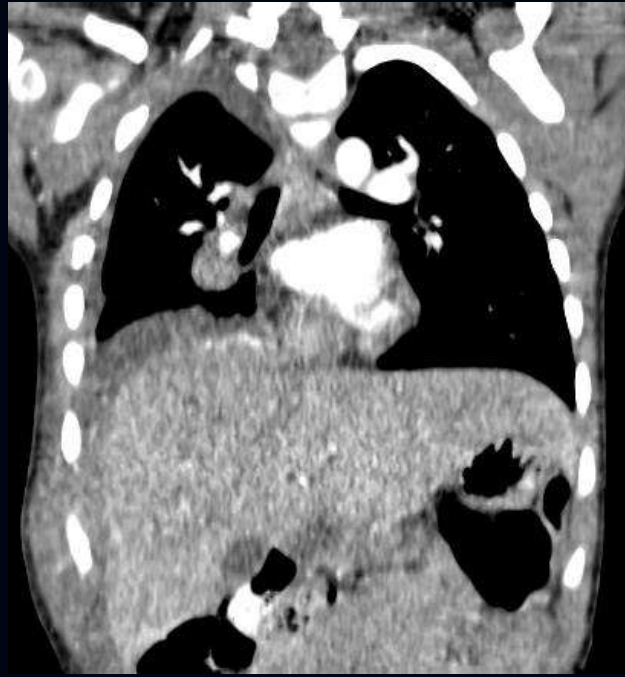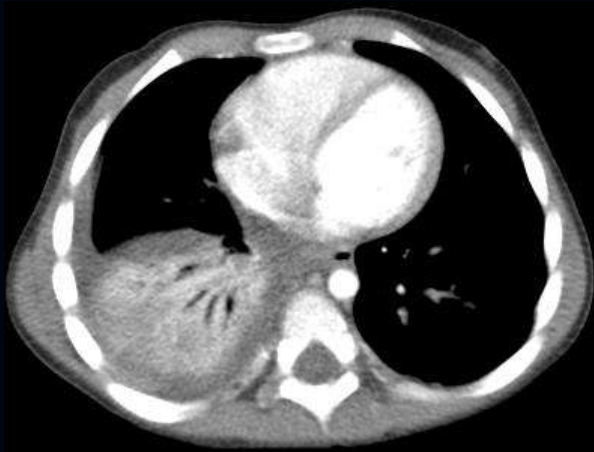
Andrew Colin, MD

Batchelor Family Professor of Cystic Fibrosis and Pediatric Pulmonology
Director, Division of Pediatric Pulmonology
Miller School of Medicine, University of Miami
Miami, Florida

Case 1: 2-year-old afebrile girl with tender lump on right lateral chest wall; normal blood count, no exposure history



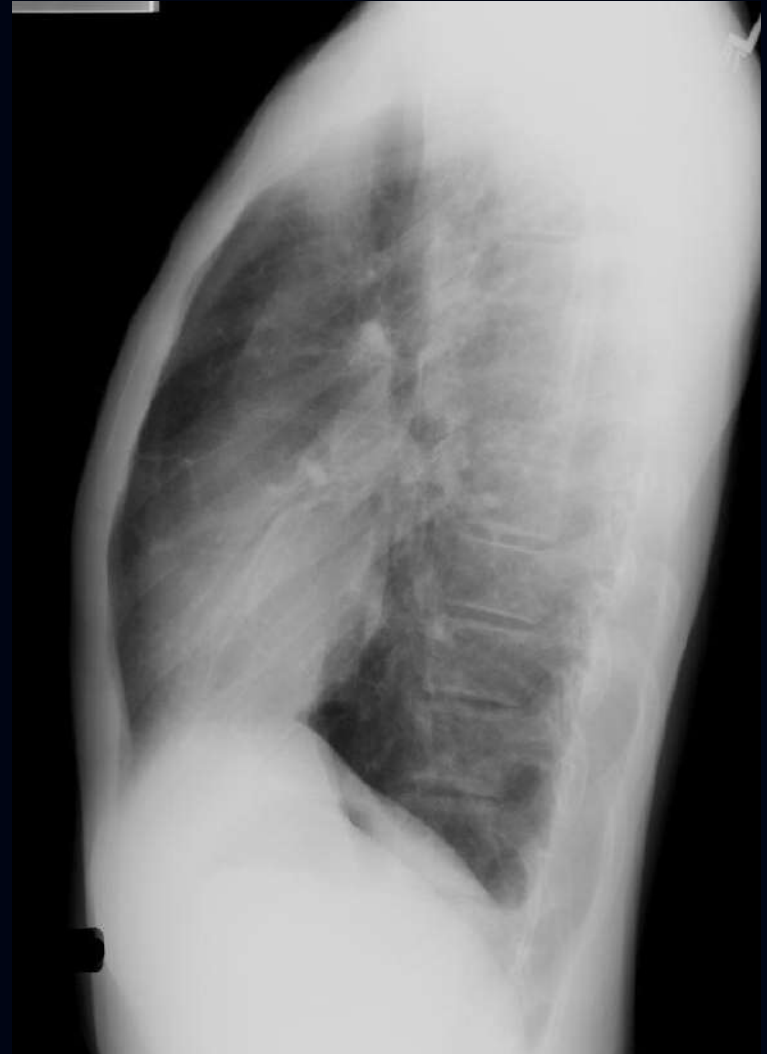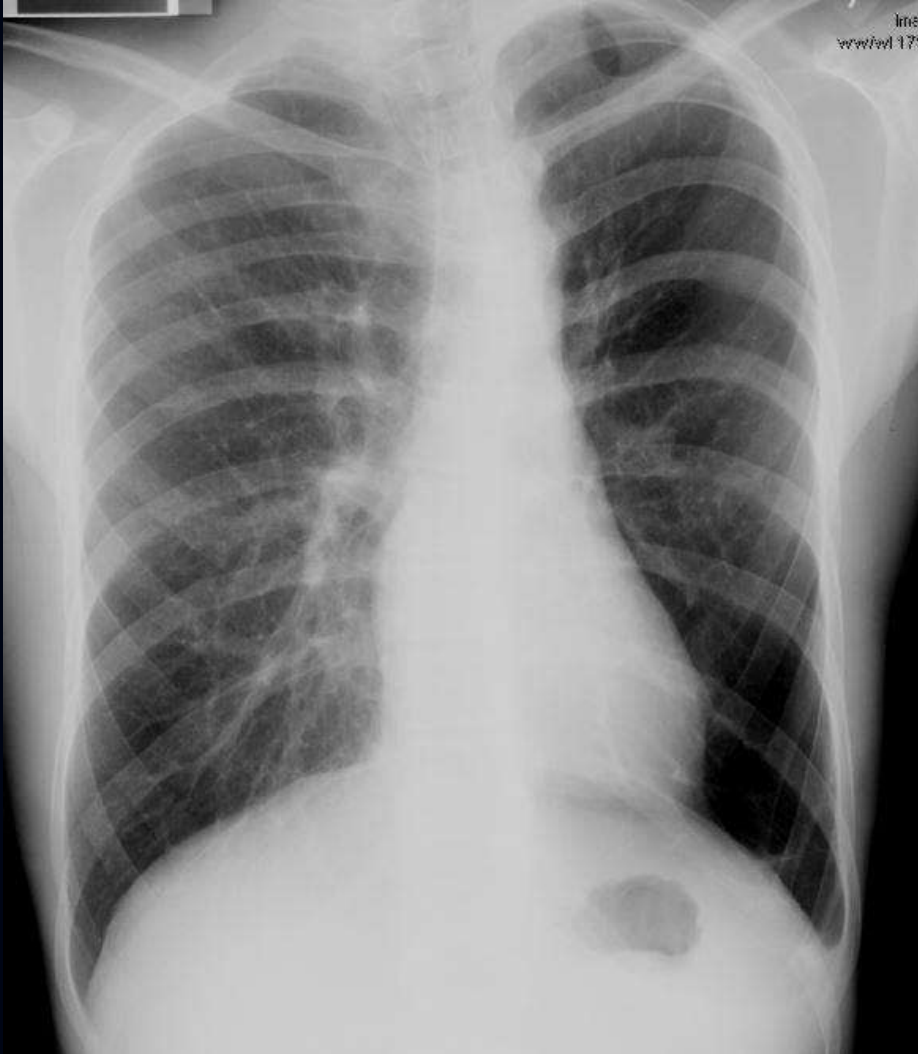Case 1: 2-year-old afebrile girl with tender lump on right lateral chest wall; normal blood count, no exposure history



What is the most likely etiology ?

- A) Neoplasm
- B) Trauma
- C) Infection
- D) Vascular malformation

Case 2: 14-year-old boy with history of “bronchitis” and “reactive airways disease”, now with fatigue



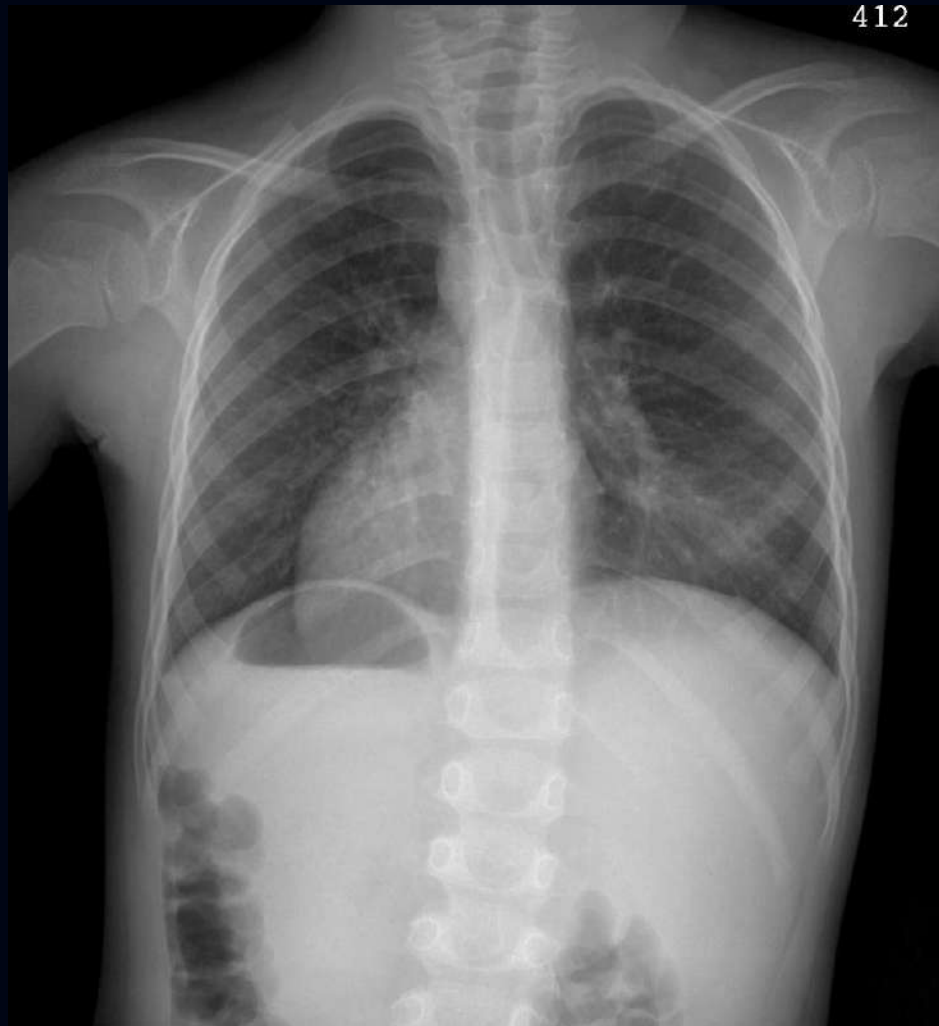
What is the name of this syndrome ?

(fill-in answer)

What is the underlying pathology ?

(fill-in answer)

Case 3: 5-year-old boy with recurrent sinonasal infections



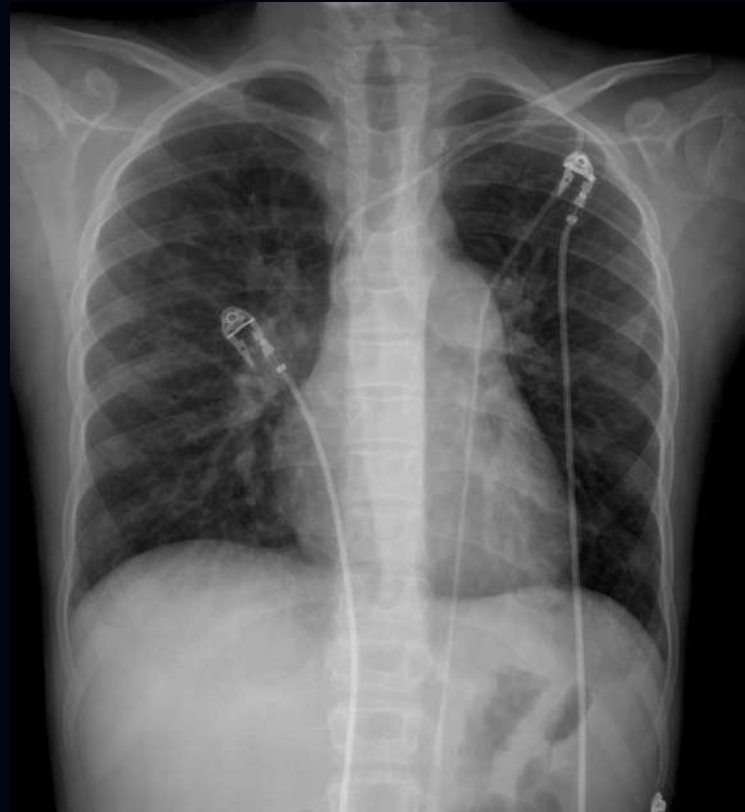
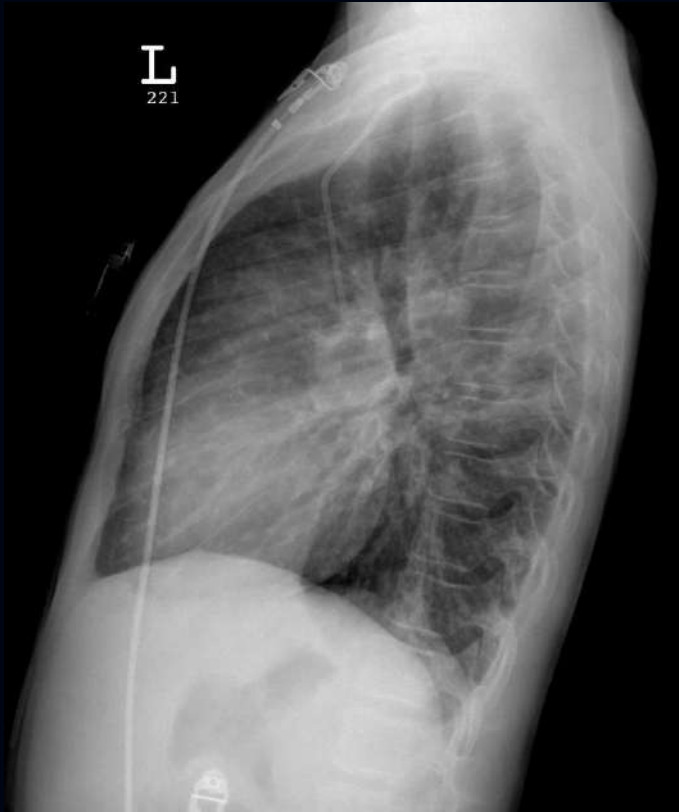What is the name of this syndrome ?

(fill-in answer)

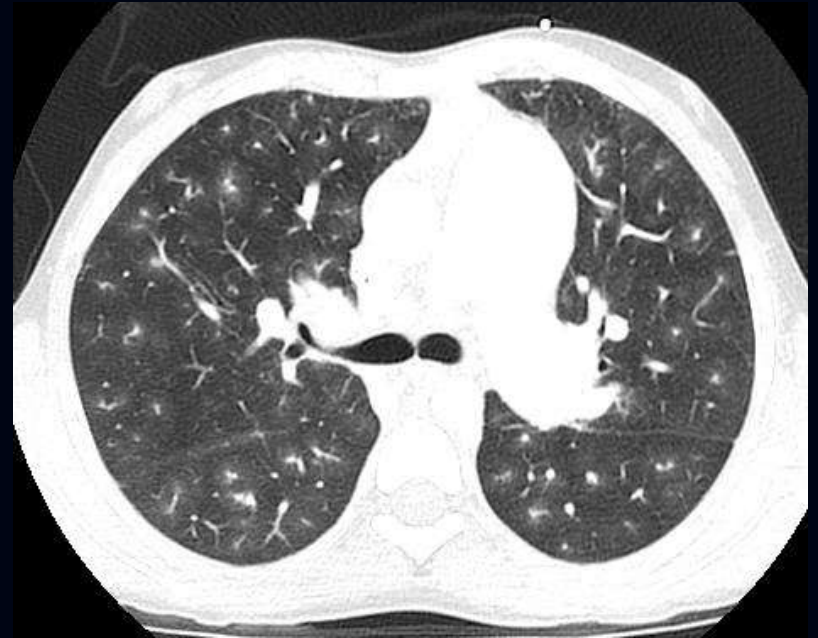
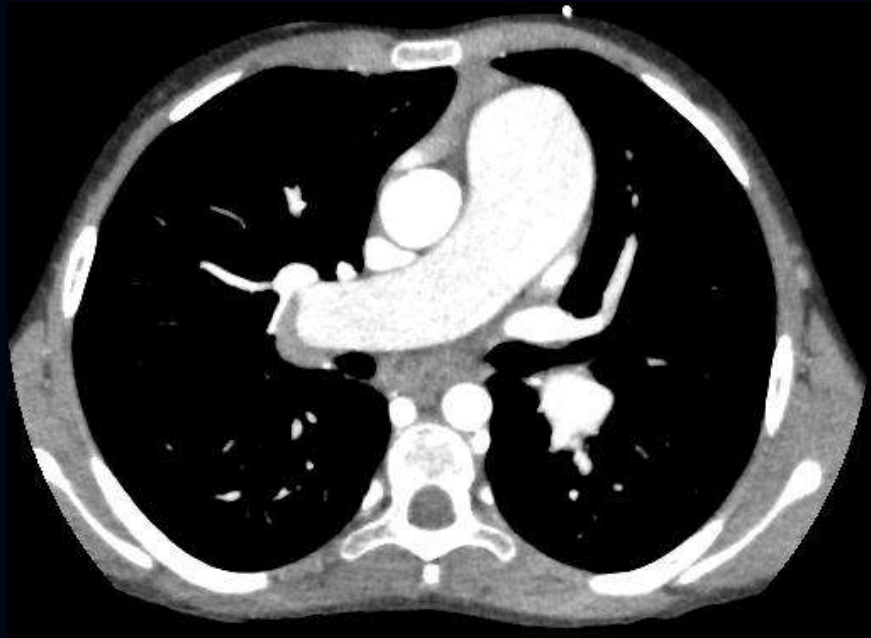What is the underlying pathology ?

(fill-in answer)

Case 4: 13-year-old girl with hemoptysis and family history of pulmonary hypertension



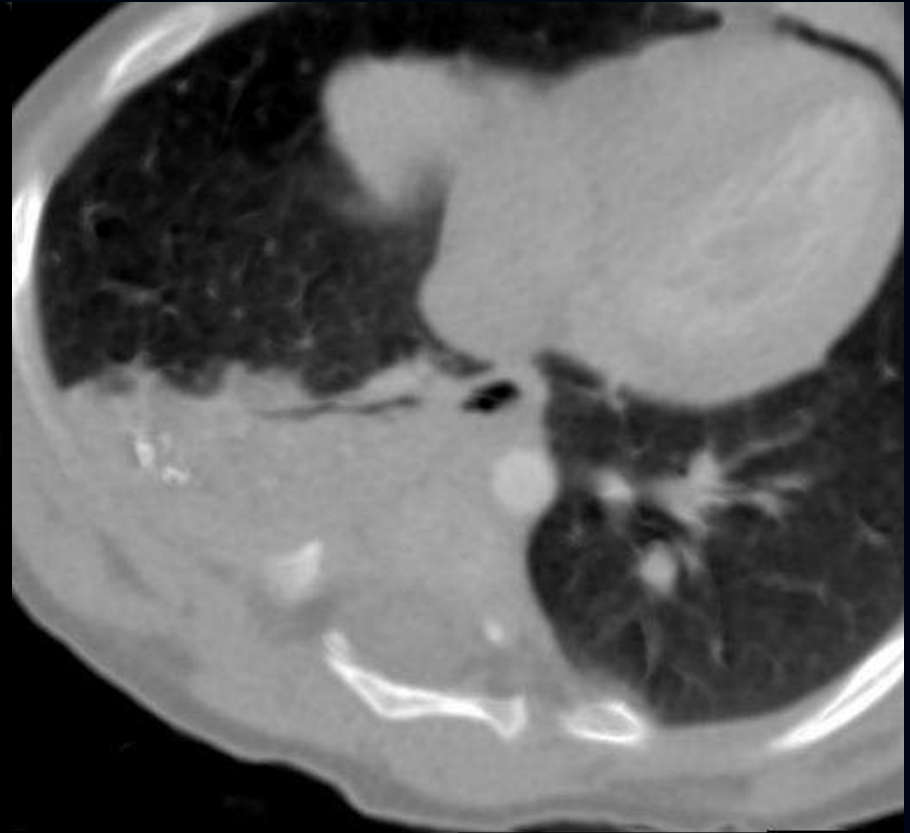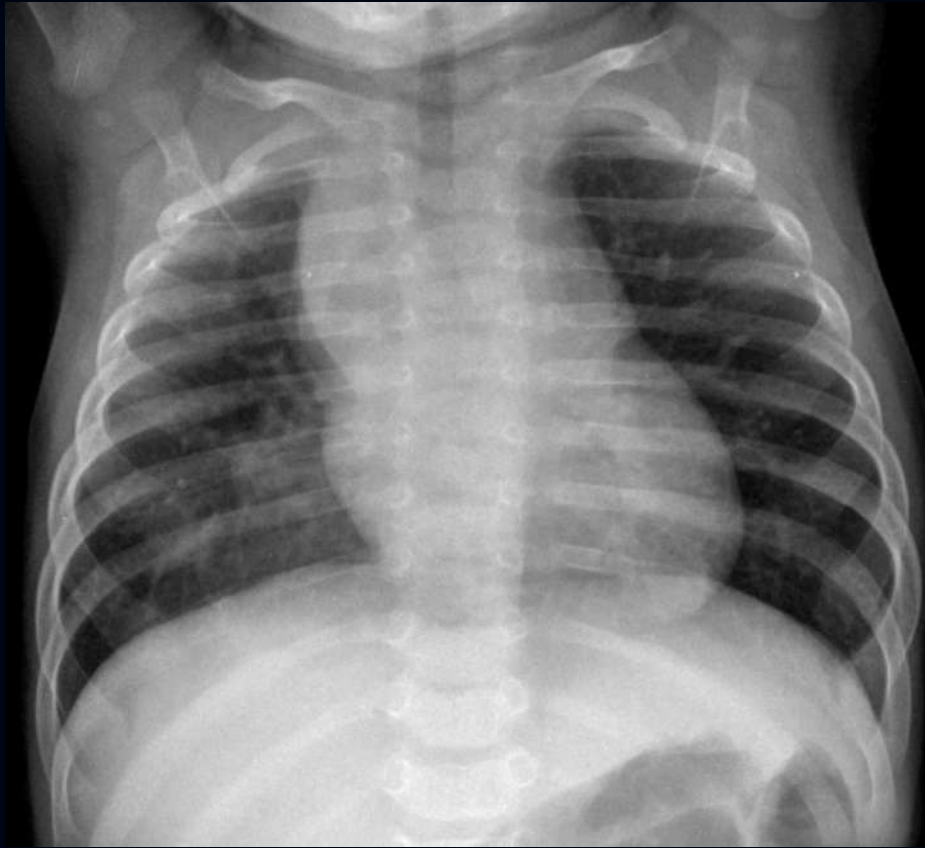
Case 4: 13-year-old girl with hemoptysis and family history of pulmonary hypertension



What is the most likely genetic association ?

- A) *BMPR2*
- B) *TBX4*
- C) *EIF2AK4*
- D) *FLNA*

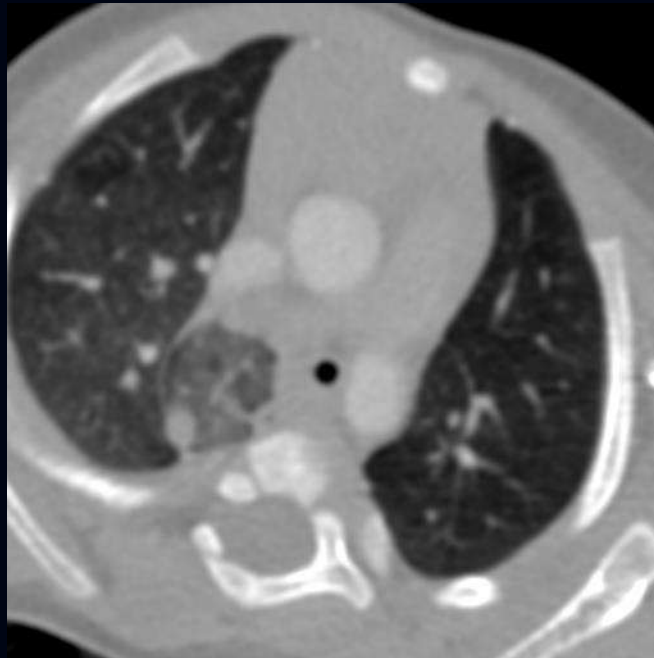
Case 5: 4-month-old girl with recurrent right lower lung pneumonias



What is the predisposing factor for the recurrent right lower lung pneumonias ?

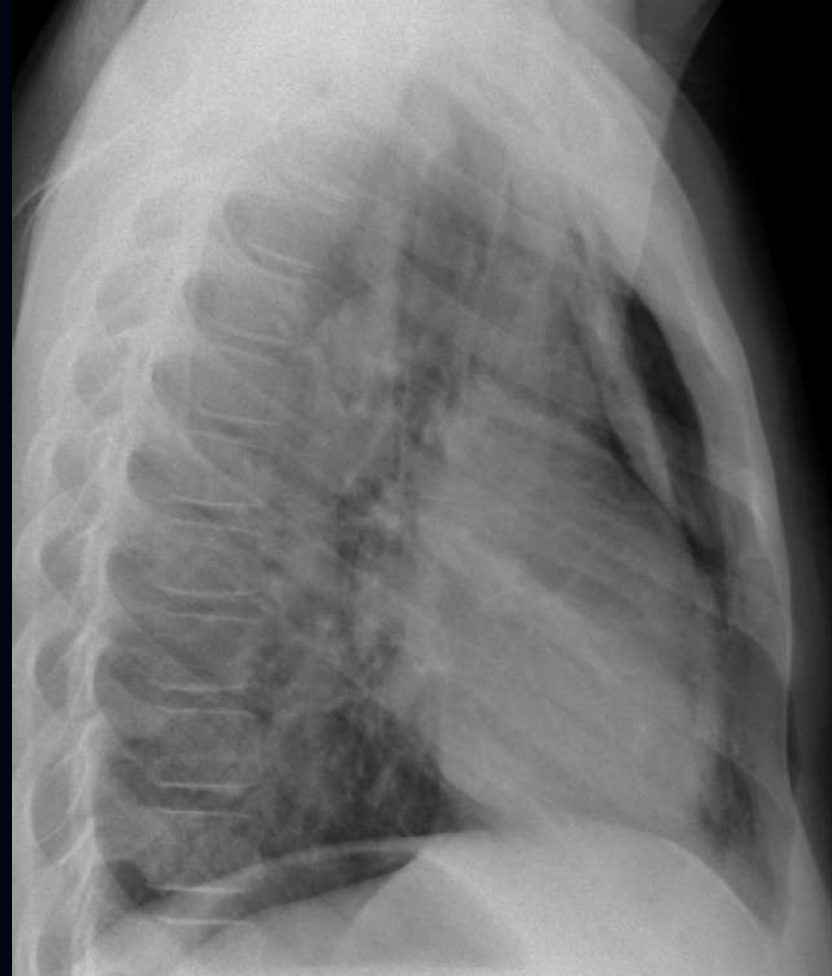
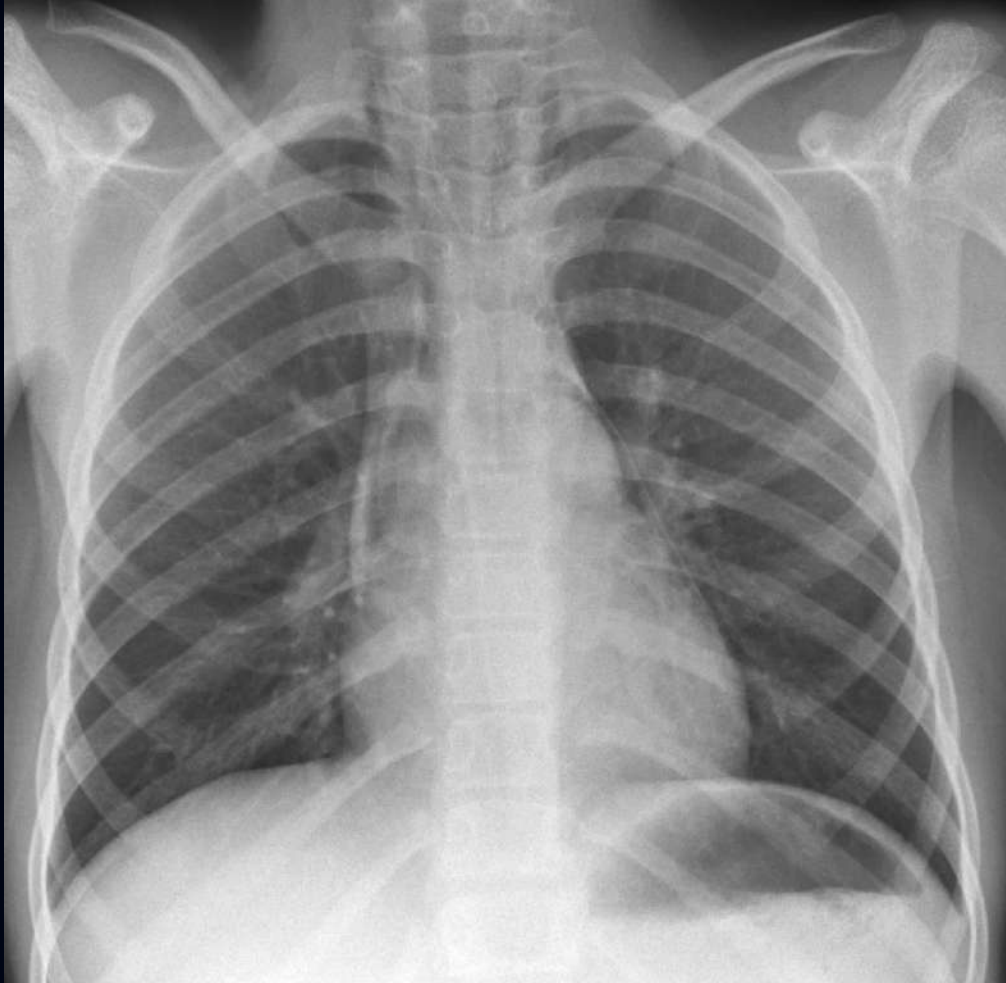
- A) Aspiration
- B) Tracheoesophageal fistula
- C) Esophageal bronchus
- D) Sequestration

What is the patient's other airway abnormality ?



(fill-in answer)

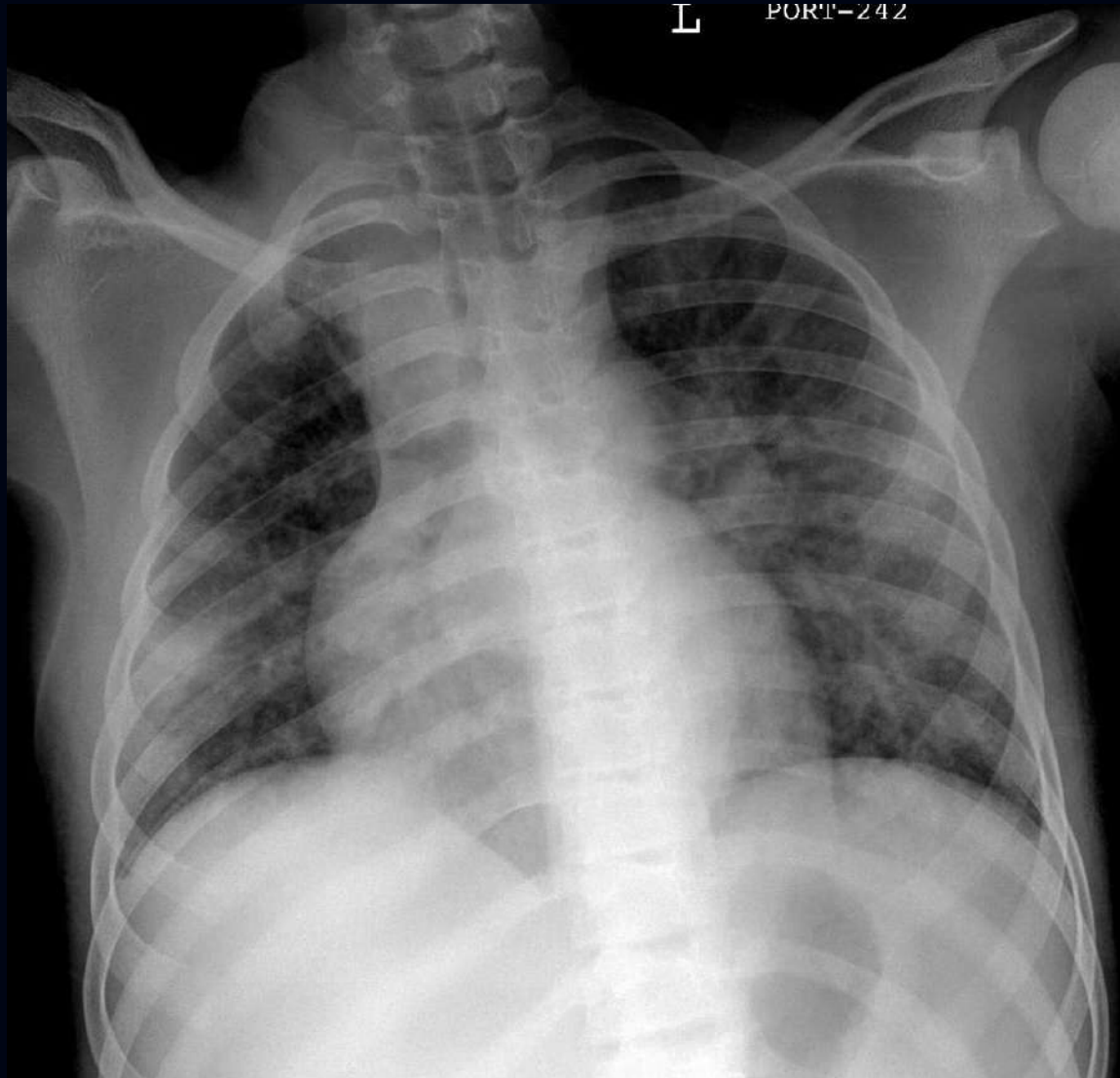
Case 6: 8-year-old asthmatic with chest pain



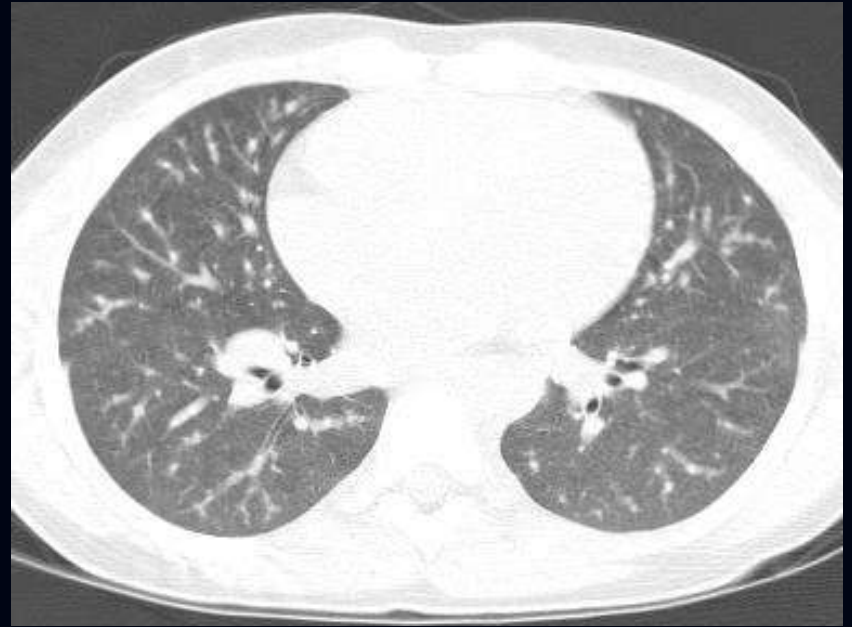
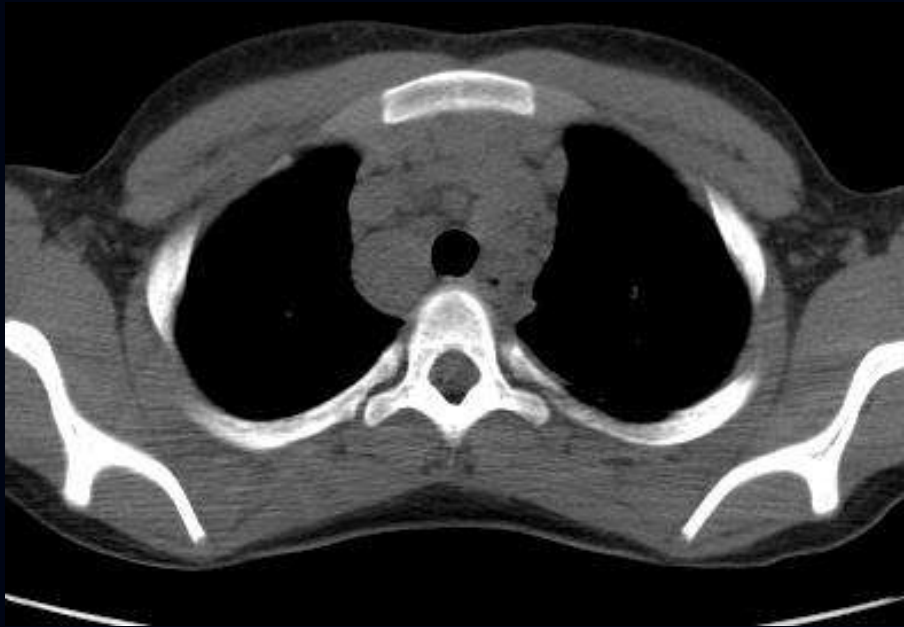What should be done next ?

- A) Chest CT
- B) Esophagram
- C) Bronchoscopy
- D) Chest tube placement
- E) Observation

Case 7: 12-year-old boy with fever, cough and eye pain



Case 7: 12-year-old boy with fever, cough and eye pain



What is the most likely diagnosis ?

- A) Granulomatosis with polyangiitis (Wegener granulomatosis)
- B) Lymphoma
- C) Tuberculosis
- D) Sarcoidosis