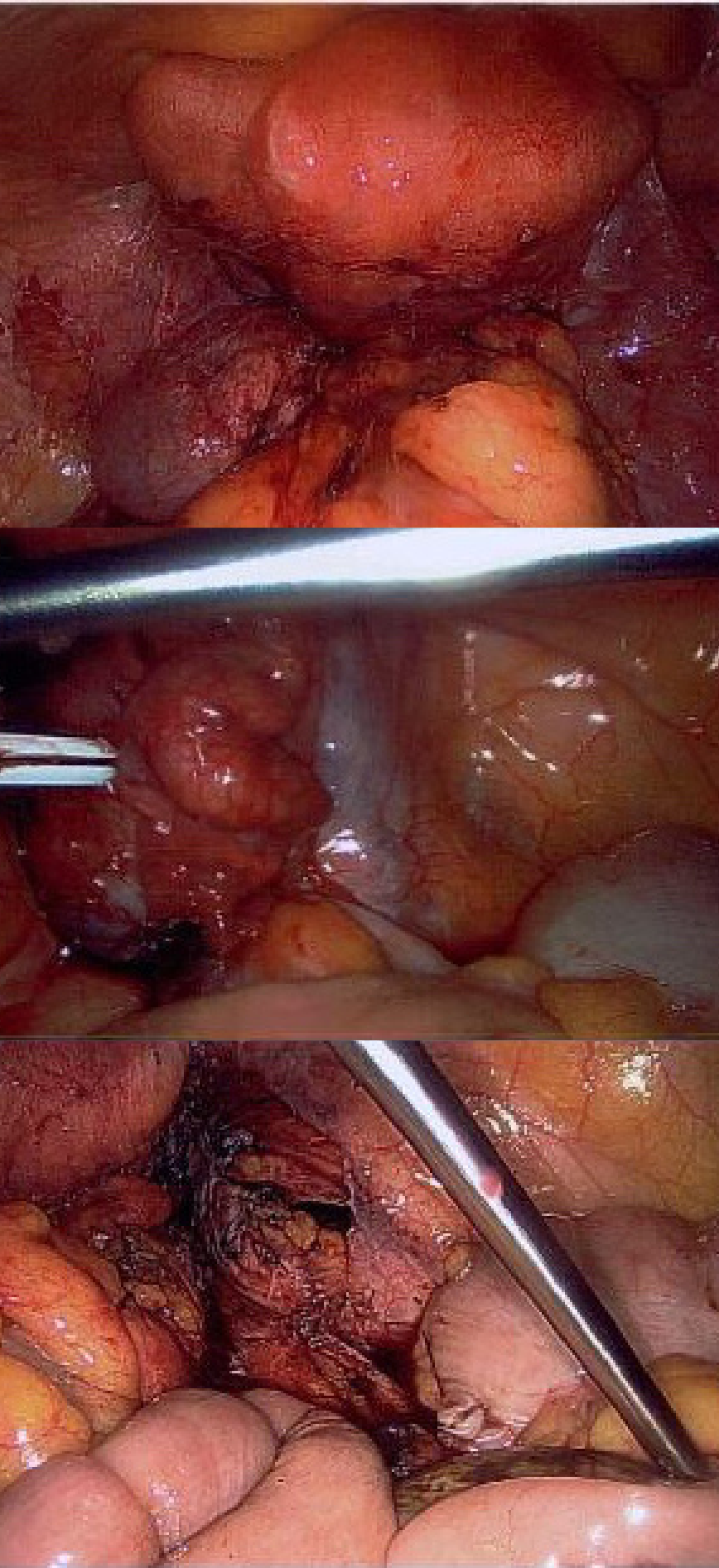



Case Report: Endometriosis of the Appendix

A Rare Presentation

Claudia Mallory | New South Wales Health



Background Endometriosis is a common gynaecological condition that can present in uncommon locations, including the appendix.

Aims This case highlights endometriosis of the appendix, which is rare and often presents incidentally or with symptoms mimicking other abdominal pathologies.

Case This case describes a 51-year-old woman, G5P1, with a history of endometriosis and pelvic pain. She was found to have adnexal masses on imaging. Her medical history included two prior laparoscopies for endometriosis excision. Notably, she did not report bowel changes but her imaging did reveal diverticular disease. During elective laparoscopic surgery, extensive stage IV endometriosis was identified, including a left hydrosalpinx, left ovarian endometrioma, and multiple right ovarian endometriomas adherent to the bowel and pelvic sidewall. Additionally, the appendix appeared swollen at the tip and was adherent to the infundibulopelvic ligament. Given these findings, an appendectomy was performed.

Results Histopathological examination confirmed right ovarian endometriotic cysts, left tubal endometriosis with hydrosalpinx, and endometriosis of the appendix.

Discussion This case highlights the importance of considering endometriosis as a potential cause of appendiceal abnormalities, even in patients without significant gastrointestinal symptoms. It underscores the need for thorough intraoperative assessment in patients with advanced endometriosis to identify and appropriately manage rare sites of disease involvement.

References 1. Guo C, Michelle Zhiyun Chen, Chiu T, G. Condous, Barto W. The appendix in endometriosis. Australian & New Zealand Journal of Obstetrics & Gynaecology. 2023 Jul 10;
2. Mabrouk M, Raimondo D, Mastronardi M, Raimondo I, Del Forno S, Arena A, et al. Endometriosis of the Appendix: When to Predict and How to Manage—A Multivariate Analysis of 1935 Endometriosis Cases. Journal of Minimally Invasive Gynecology. 2020 Jan;27(1):100–6.
3. Saleem A, Navarro P, Munson JL, Hall J. Endometriosis of the appendix: Report of three cases. International Journal of Surgery Case Reports. 2011;2(2):16–9.