

# A RARE CASE OF ECLAMPSIA COMPLICATED BY POSTERIOR REVERSIBLE ENCEPHALOPATHY SYNDROME AND REVERSIBLE CEREBRAL VASOCONSTRICTION SYNDROME

Rahim A<sup>1,2</sup>, Aridas A<sup>2</sup>, Florescu G<sup>3</sup>

<sup>1</sup>Monash University <sup>2</sup>Department of Obstetrics and Gynaecology - Monash Health <sup>3</sup>Department of Diagnostic Imaging – Monash Health

## BACKGROUND

Reversible cerebral vasoconstriction syndrome (RCVS) represents a group of conditions demonstrating reversible narrowing of cerebral arteries. Posterior reversible encephalopathy syndrome (PRES) is defined by clinical findings of a headache, visual disturbances and seizures with radiologic features of oedema in the white-matter. Occasionally, these conditions co-exist.

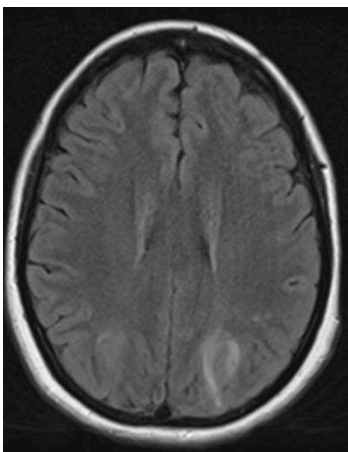


Image 1 (above): MRI brain showing features of PRES with FLAIR hyperintensity demonstrated in the bilateral parietal occipital lobes

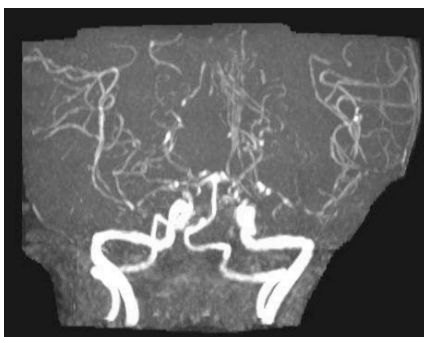

Image 2 (above): MRA brain showing multiples areas of constriction within multiple vessels particularly affecting the anterior circulation, middle cerebral arteries and supraclinoid ICAs

Image 3 (right): Progress MRA brain demonstrating improvement with greater flow signal in the major branches of the circle of Willis and reduction in the degree of beading and irregularity evident previously

## CASE

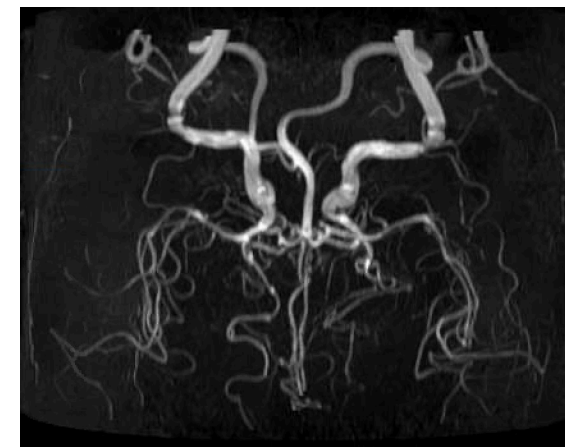A 28-year-old, otherwise healthy, primiparous female presented to hospital following two seizures at 32-weeks-gestation. She had a 36-hour history of gradual onset headache and right-upper-quadrant abdominal pain. She was hyperreflexic, had uncontrolled clonus and blood pressure (BP) peaked at 190/100mmHg. Management included a magnesium sulphate infusion, intravenous labetalol and hydralazine boluses. Bloods were unremarkable and a caesarean section was performed for a fetal bradycardia. Postoperatively she developed complete visual loss and then a right-homonymous-inferior-quadrantanopia. MRI brain confirmed appearances suggestive of PRES with coexisting RCVS. Regular nimodipine was commenced and BP was titrated with labetalol. Her headache resolved instantly and vision improved by day 6. A progress MRI brain indicated ongoing changes of PRES but an improvement in arterial flow. She was discharged on nimodipine and labetalol with BP monitoring as an outpatient.

## RESULTS

The classic presentation of RCVS is a thunderclap headache with occasional neurological deficits. Antenatal presentations of RCVS are rare and the treatment of vasoconstriction relies on observational data.

## DISCUSSION

This is an atypical presentation of an antenatal case of eclampsia complicated by concurrent PRES and RCVS. It demonstrates effective management with nimodipine and is the first such documented case in Australia.



## REFERENCES

1. Ueno S, Takeda J, Maruyama Y, Makino S, Miyamoto N, Itakura A. Antepartum eclampsia with reversible cerebral vasoconstriction and posterior reversible encephalopathy syndromes. J Obstet Gynaecol Res 2020; 46(10):2147-2152.
2. Tanaka K, Matsushima M, Matsuzawa Y, Wachi Y, Izawa T, Sakai K, Kobayashi Y et al. Antepartum reversible cerebral vasoconstriction syndrome with pre-eclampsia and reversible posterior leukoencephalopathy. J Obstet Gynaecol Res 2015; 41:1843-1847.
3. Pop A, Carbonnel M, Wang A, Josserand J, Condet A, Auliac S, Ayoubi J-M. Posterior reversible encephalopathy syndrome associated with reversible cerebral vasoconstriction syndrome in a patient presenting with postpartum eclampsia: A case report. J Gynecol Obstet Hum Reprod 2019; 48(6):431-434.