

# Cornual Ectopic Pregnancy managed laparoscopically: A Case Report

Dr Sally Cash

Department of Obstetrics and Gynaecology, Westmead Hospital

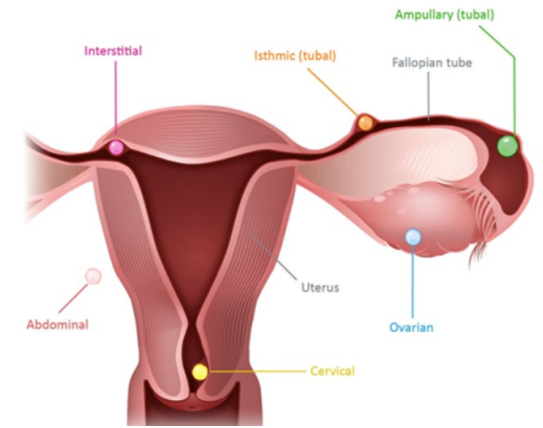


Image 1: Sites of ectopic implantation<sup>5</sup>

## Background

Cornual (also known as interstitial) pregnancy constitutes less than 4% of all ectopic pregnancies, making it a rare and extremely challenging condition to diagnose<sup>1</sup>. As the implantation site is within the intrauterine portion of the fallopian tube, the ectopic has the potential to grow larger than standard ectopic pregnancies by the time of presentation due to the distensibility of this location<sup>2</sup>. In consequence, cornual pregnancies are typically diagnosed later than other types of ectopic pregnancies and are therefore associated with a higher rate of maternal morbidity and mortality.

## Case

A 35-year-old woman, G7P4, presented to a tertiary emergency department with acute, severe lower abdominal pain with voluntary guarding, emesis and hypotension. She had a positive serum BHCG of 18923 IU/L with a history of an unknown last menstrual period, but a positive home urinary pregnancy test the day prior.

Due to haemodynamic instability and increasing analgesic requirements, she underwent an emergency diagnostic laparoscopy. Intraoperatively, a unilateral salpingectomy and cornuostomy was performed after a ruptured right cornual ectopic pregnancy was identified. Her operation was complicated by a 1600mL haemoperitoneum. Post-operatively, she was admitted to the high dependency unit due to ongoing hypotension and a metabolic acidosis (pH of 7.26). In total she received 2 units of fresh-frozen plasma, 2 units cryoprecipitate and 3 units of packed red blood cells.

She had stable post-operative course and was stepped down to the ward on day 2. She was discharged home on day 3 with a haemoglobin of 83 g/L. She had follow-up arranged with the outpatient gynaecological clinic in a few weeks prior to discharge for a formal debrief.

## Discussion

Life-threatening haemorrhage from a ruptured cornual ectopic pregnancy can result in a 2-2.5% mortality rate, which is seven times the average for all ectopic pregnancies<sup>3</sup>. Prompt recognition and management of this condition is therefore crucial. The diagnosis of cornual pregnancy can be made on ultrasound or MRI, however in patients without imaging who are hemodynamically unstable, such as in this case, the diagnosis is typically made intraoperatively. Appropriate first line management is based on several factors including patients symptoms, timely diagnosis, size of the pregnancy, haemodynamic stability and desires for future fertility<sup>3</sup>. The traditional treatment of cornual pregnancy was laparotomy with cornual resection or hysterectomy, however less invasive surgical approaches are being used such as laparoscopic cornuostomy or wedge resection<sup>4</sup>. These have demonstrated better outcomes for patients including reduced intra-operative complications and reduced inpatient stay<sup>4</sup>.

## References

1. Varun, N., Nigam, A., Elahi, A. A., & Jain, A. (2018). Cornual ectopic pregnancy: laparoscopic management step by step. *BMJ Case Reports*; 2018:bcr-2017-223998. doi: 10.1136/bcr-2017-223998
2. Faraj, R., & Steel, M. (2007). Review Management of cornual (interstitial) pregnancy. *The Obstetrician & Gynaecologist*. 2007;9-249-255.
3. Brincat, M., Bryant-Smith, A. & Holland, T.K. (2019). The diagnosis and management of interstitial ectopic pregnancies: a review. *Gynaecological Surgery* 16, 2. <https://doi.org/10.1186/s10397-018-1054-4>
4. Warda, H., Mamik, M, M., Ashraf, M. & Abuzeid, M, I. (2014). Interstitial ectopic pregnancy: conservative surgical management. *Journal of The Society of Laparoscopic & Robotic Surgeons*. Apr-Jun;18(2):197-203. doi: 10.4293/108680813X13753907292836.
5. Royal College of Obstetricians & Gynaecologists. (2016). *Ectopic Pregnancy*. <https://www.rcog.org.uk/for-the-public/browse-all-patient-information-leaflets/ectopic-pregnancy-patient-information-leaflet/>