

Specialty Services

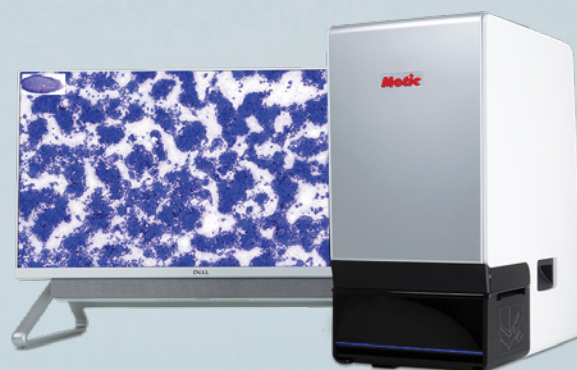
Clinical Pathology in your practice...
on demand! Wield the power of digital
telectology with board certified clinical
pathologists across the globe.

Comprehensive reports in minutes

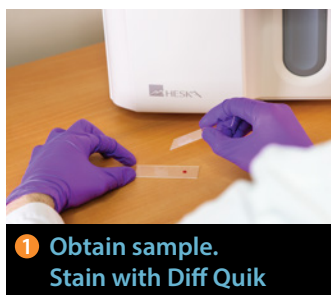STAT service

Real-time chat support

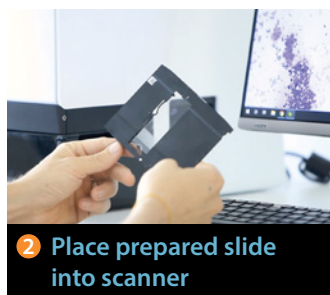
Board-certified clinical pathologists



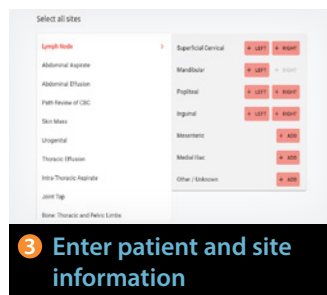
Easy Operation



1 Obtain sample.
Stain with Diff Quik



2 Place prepared slide into scanner



3 Enter patient and site information



Pathologist review and report

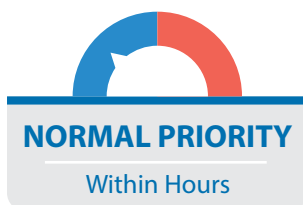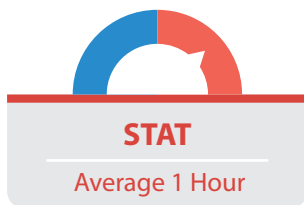
The HeskaView Telecytology™ Advantage

Provide better diagnosis and treatment for difficult or time-consuming cases.

- Elevate standard of patient care
- Expedite client communication
- Eliminate delays in slide review
- Move on to next step diagnostics and treatment quickly



Turn-around time priorities...



Add a specialty service to your practice without hiring a specialist!

Digital telecytology allows timely access to veterinary clinical pathologists who can assist with diagnostic evaluation of your patients. Choose STAT* or Normal Priority[§] turn-around time options. Whether you are a cytology novice or expert, the board-certified pathologists at HeskaView Specialty Services can help with everything from blood smears to fine needle aspirates to pre-surgical planning and more.

Examples of Submissions

- CBC Pathology Review
- Dermal & Subcutaneous Masses
- Lymph Nodes
- Body Cavity Effusions
- Joint Taps
- Oral & Nasal Masses
- Abdominal Organs & Masses
- Thoracic Organs & Masses
- BAL/TTW
- Urogenital Cytology
- Vaginal Cytology
- Bone Lesions
- Bone Marrow Cytology
- CSF Cytology and more...

Get answers to difficult and time-consuming cases

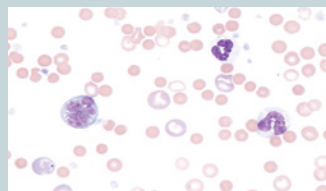


Image source: 4 year old M/C Cocker Spaniel – peripheral blood film: **Immune mediated hemolytic anemia?**

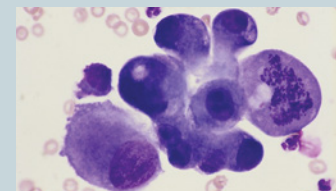


Image source: 12 year old F/S DSH – 1.5 cm diameter mass near the angle of the jaw: **Cancer or inflammation?**

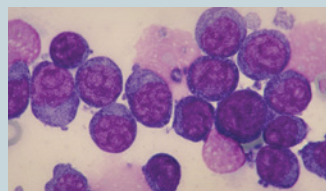


Image source: 6 year old M/C GSD – 3.5 cm soft mass in submandibular: **Lymphadenitis, lymphoma or a sialocoele?**

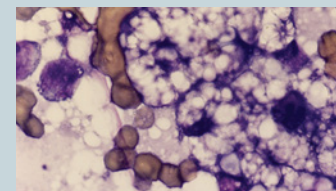



Image source: 8 year old F/S DSH – hepatomegaly and increased liver enzymes: **Hepatic lipidosis or cancer?**



*For preliminary interpretation. Additional STAT charges apply. [§]Average turnaround times may vary. Longer turnaround times may be experienced during peak submission times, overnights and on weekends. ©2023 Heska Corporation. All Rights Reserved. Specifications and appearance may be changed without notice. Motic is a registered trademark of Motic Instruments Inc. HESKA is a registered trademark and HeskaView Telecytology is a trademark of Heska Corporation in the United States and in other countries AU21LT0403_003