

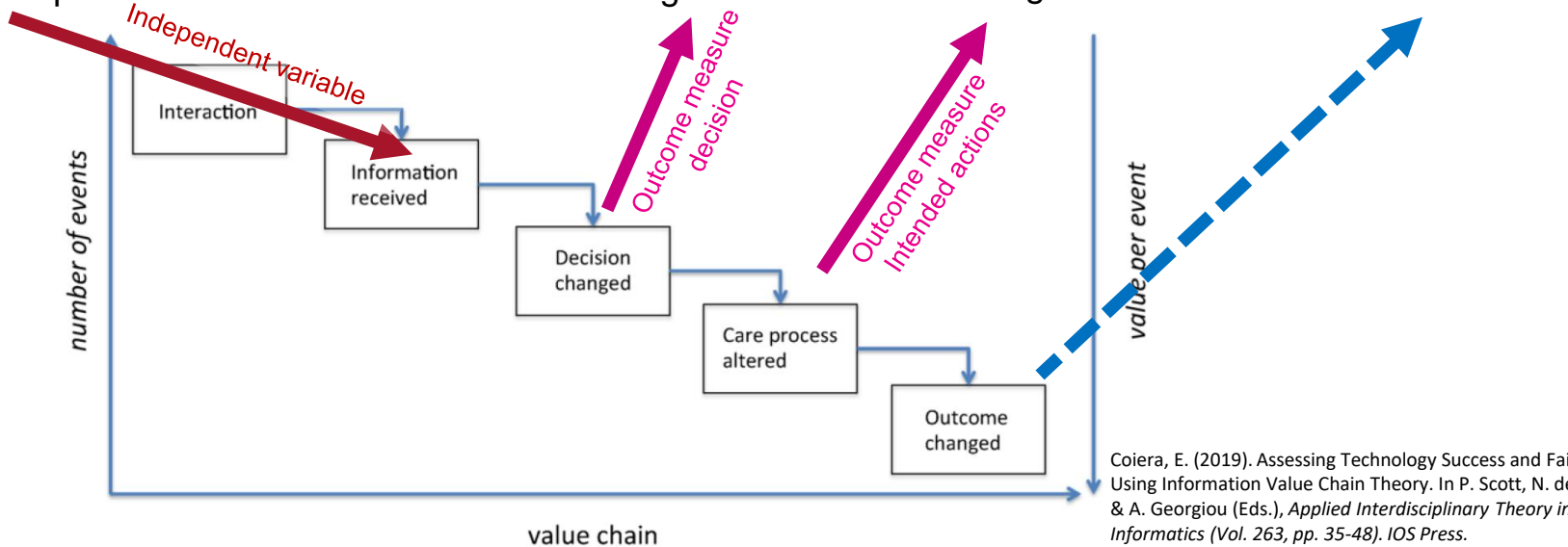
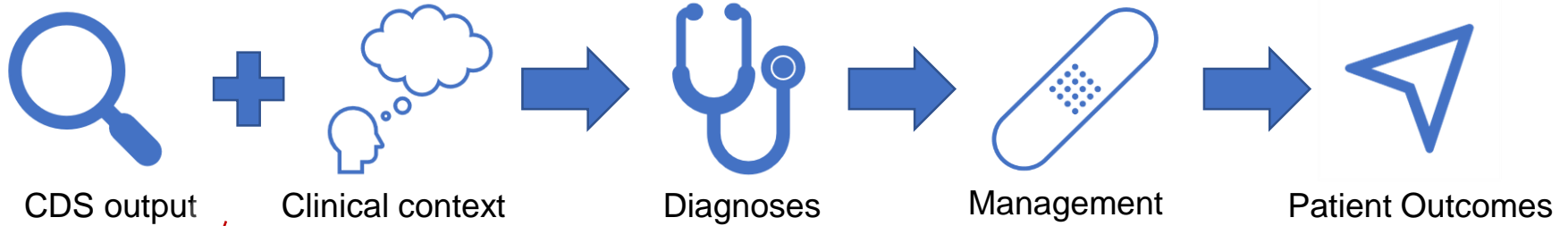
@David\_Lyell

## Using Clinical Simulation to Evaluate AI-enabled Decision Support

David LYELL, Adriaan LUSTIG, Kate DENYER, Satya VEDANTAM & Farah MAGRABI

*Macquarie University*





Coiera, E. (2019). Assessing Technology Success and Failure Using Information Value Chain Theory. In P. Scott, N. de Keizer, & A. Georgiou (Eds.), *Applied Interdisciplinary Theory in Health Informatics* (Vol. 263, pp. 35-48). IOS Press.



## Case study: Evaluating overreliance on CDS

**Participants:** 34 students enrolled in the final two years of the Doctor of Medicine (MD) program at Macquarie University.

**Task:** *Diagnose* hypothetical patient presentations where chest x-ray is indicated.

**Study design:** Quality of CDS (correct CDS, incorrect CDS and no CDS)

**Outcome measures:** Diagnostic accuracy, trust in CDS and information seeking behaviours.

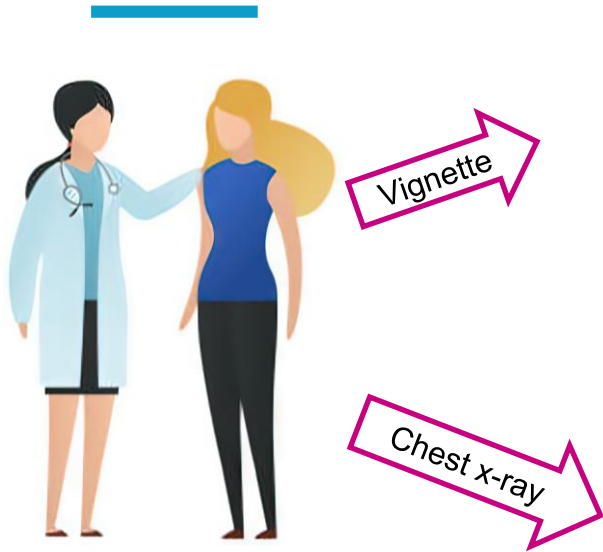
**Setting:** n=21 completed online study, n=13 attended on campus laboratory for eye tracking.

**Randomisation:** Order of presentation and *allocation of scenarios to conditions* (between participants).

Study approved by Macquarie University Human Research Ethics Committee (ref 520231096449782).



## Case study: Simulated patient presentation

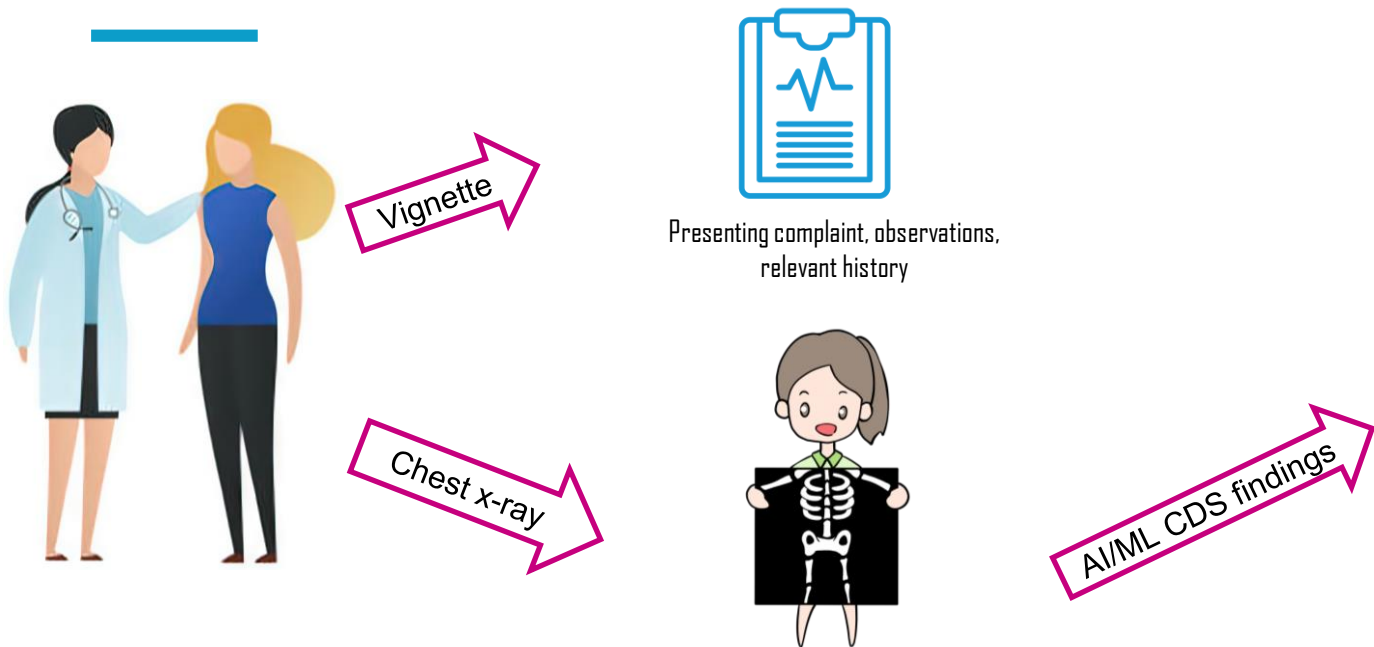


Presenting complaint, observations,  
relevant history





## Case study: Simulated CDS aided chest x-ray interpretation





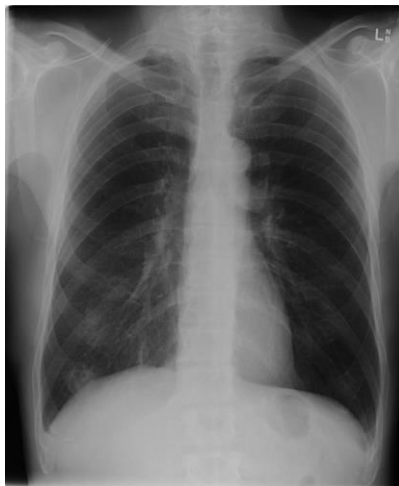## Case study: Patient scenario **with no CDS (control)**



Vignette

Chest x-ray

66yo male presents with increasing shortness of breath, decreased exercise tolerance in recent weeks & long-standing productive cough. 40-pack-year smoking history. History: hypertension, dyslipidaemia and Type 2 Diabetes Mellitus. Vitals: RR 22 HR 86 BP 140/90 SpO2 91% RA Temp 36.7 C



Scenarios and wizard of Oz CDS created by Kate Denyer & Adriaan Lustig.

Validated by a Fellow of the Royal Australian and New Zealand College of Radiology.



## Case study: Patient scenario with CDS



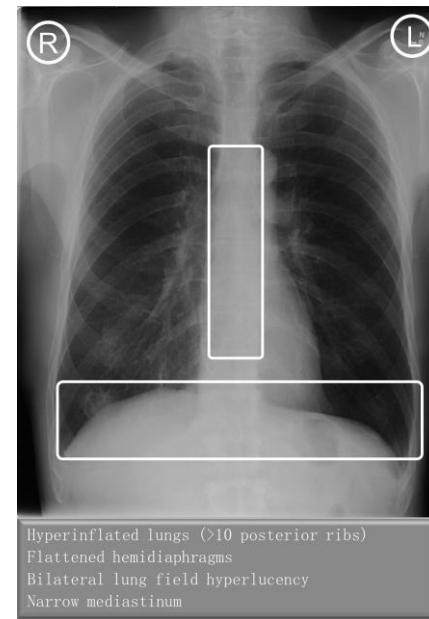
Vignette

Chest x-ray

66yo male presents with increasing shortness of breath, decreased exercise tolerance in recent weeks & long-standing productive cough. 40-pack-year smoking history. History: hypertension, dyslipidaemia and Type 2 Diabetes Mellitus. Vitals: RR 22 HR 86 BP 140/90 SpO2 91% RA Temp 36.7 C



AI/ML CDS findings





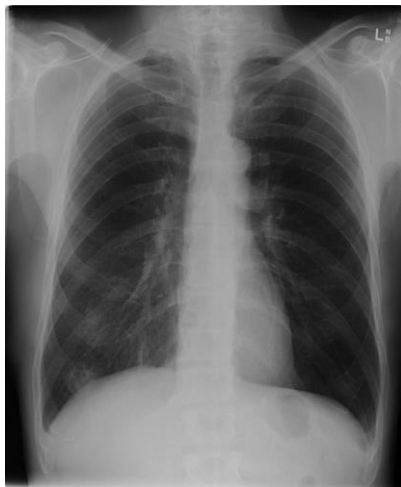## Case study: Patient scenario **with incorrect CDS**



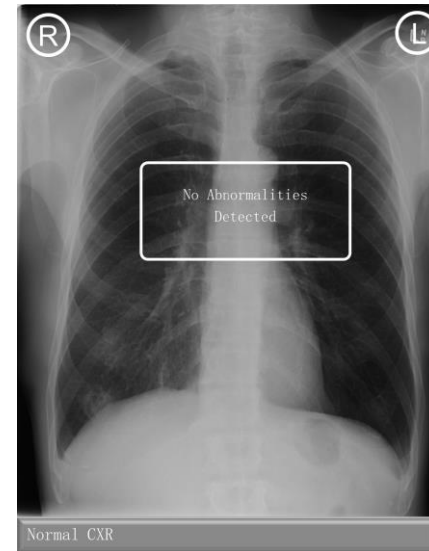
Vignette

Chest x-ray

66yo male presents with increasing shortness of breath, decreased exercise tolerance in recent weeks & long-standing productive cough. 40-pack-year smoking history. History: hypertension, dyslipidaemia and Type 2 Diabetes Mellitus. Vitals: RR 22 HR 86 BP 140/90 SpO2 91% RA Temp 36.7 C



AI/ML CDS findings



# MEDINFO23

8 - 12 JULY 2023 | SYDNEY, AUSTRALIA



Open Health  
  Imaging Foundation

Open source medical imaging  
viewer  
ohif.org



Experiment development &  
delivery platform  
gorilla.sc

Series Zoom Levels Pan Insert Rotate Right Flip H Flip V Reset View Length Angle Clear Layout

Stack Scroll Zoom Levels Pan Reset View Prev Finding Next Finding Layout

842 x 1024 Zoom: 94% W: 255 L: 127

1361 x 1982 Zoom: 48% W: 255 L: 127

Hyperinflated lungs (>10 posterior ribs)  
Flattened hemidiaphragms  
Bilateral lung field hyperlucency  
Narrow mediastinum

A 66-year-old man presents to ED with increasing shortness of breath. Over the last few weeks his exercise tolerance has been decreased from 1000 m to 50 m. He has a long-standing productive cough, which he feels has become more frequent, and a 40-pack-year smoking history. Past medical history includes hypertension, dyslipidaemia and Type 2 Diabetes Mellitus. His medications include atorvastatin, telmisartan and metformin.  
Vitals: RR 22 HR 86 BP 140/90 SpO2 91% RA Temp 36.7 C

Is this a normal chest x-ray?  Yes  No

Please rate your confidence in the provisional diagnosis?

Very Unconfident  Unconfident  Slightly Unconfident  Neither  Slightly Confident  Confident  Very Confident

Submit and continue

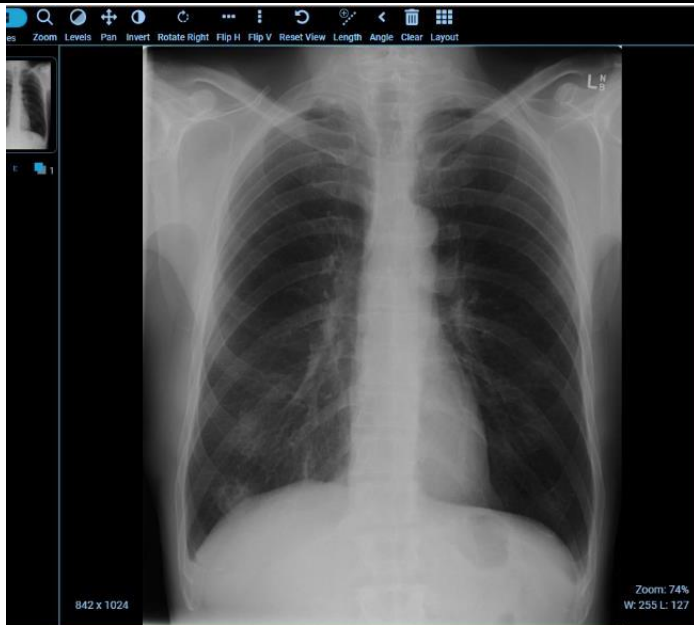


Open Health  
  Imaging Foundation

Open source medical imaging  
viewer  
ohif.org



Experiment development &  
delivery platform  
gorilla.sc



65-year-old man presents to ED with increasing shortness of breath  
for the last few weeks his exercise tolerance has been decreased from 1000 m to 50 m. He has a long-standing productive  
cough, which he feels has become more frequent, and a 40-pack-year smoking history.  
His medical history includes hypertension, dyslipidaemia and Type 2 Diabetes Mellitus. His medications include atorvastatin,  
lisin, aspirin, metformin, and mefloquine.  
Vitals: RR 22 HR 86 BP 140/90 SpO2 91% RA Temp 36.7 C

Decision support is not available for this patient

Is this a normal chest x-ray?  Yes  No

Please rate your confidence in the provisional diagnosis?

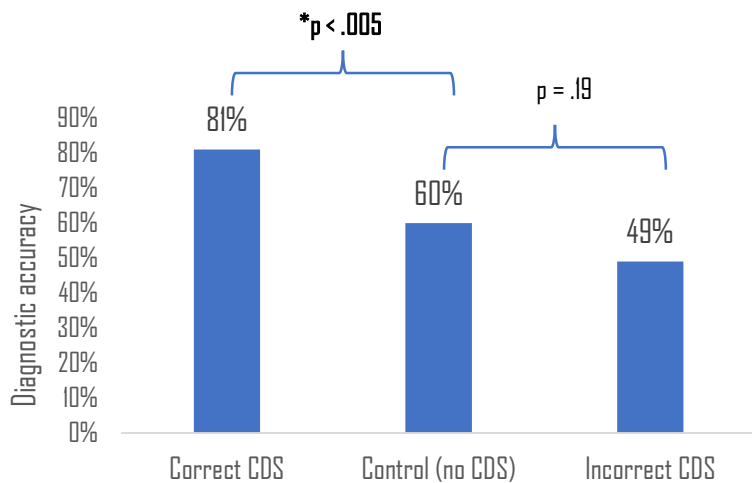
Very Unconfident  Unconfident  Slightly Unconfident  Neither  Slightly Confident  Confident  Very Confident

Submit and continue

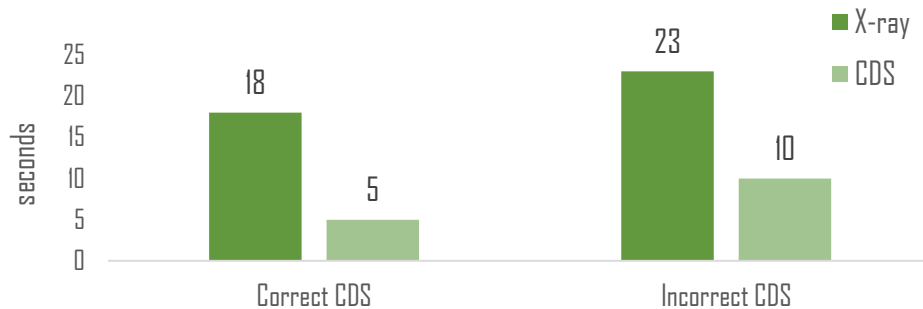


## Results

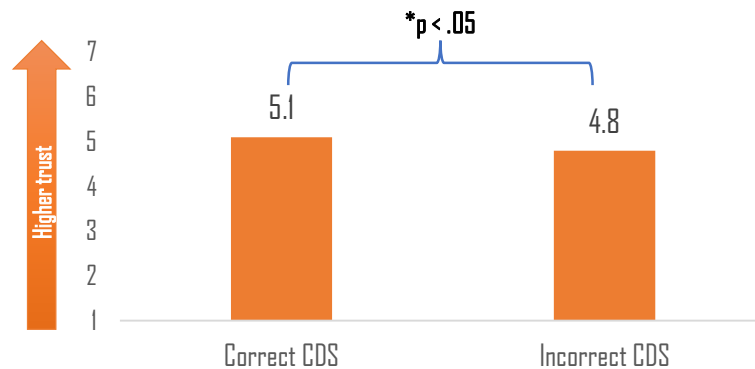
Diagnostic accuracy n=34



Fixations on X-ray and CDS n=13



Trust in CDS n=34





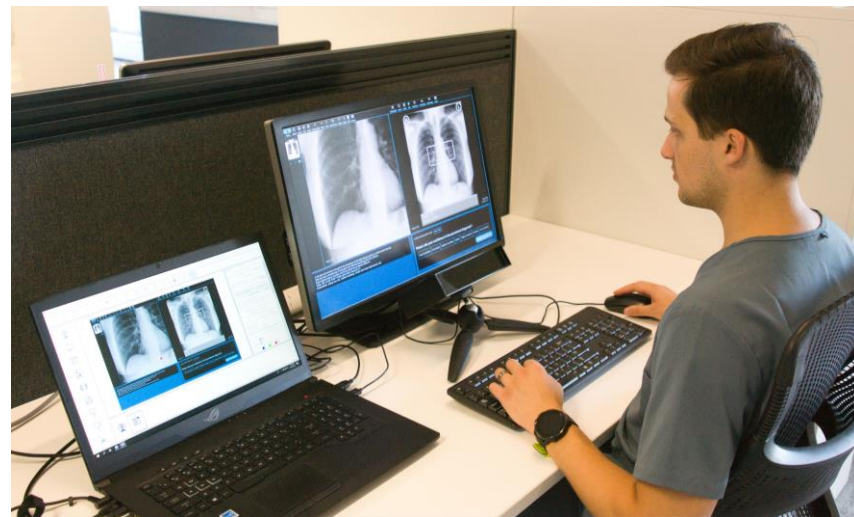
## Conclusion: Evaluating AI/ML CDS with simulated clinical decision-making tasks

Simulation studies permits

- Patient- and risk-free.
- *Experimental control.*
  - Ability to draw causal inferences.
  - Test theory.
  - Independent variables.
    - CDS characteristics.
    - Participant characteristics.
    - Scenario characteristics.

Role of simulation studies

- Augment/supplement other evaluation methods.



Investigator Adriaan Lustig demonstrating study with eye tracking.