

Rare Tumours in HIV

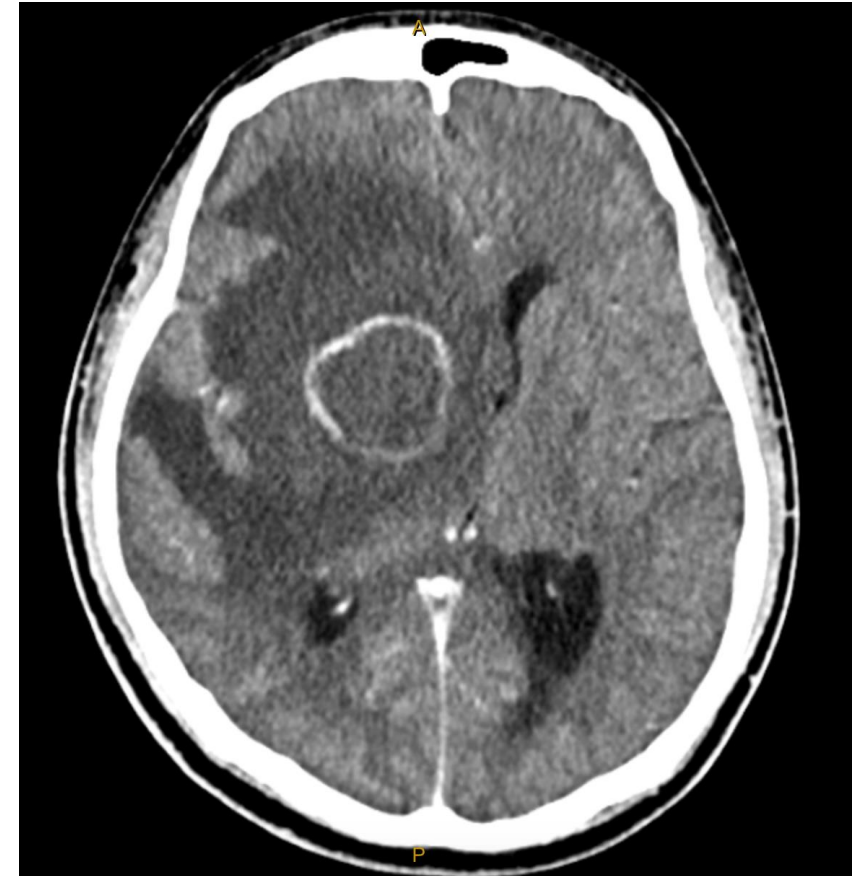Dr Michael Riceman

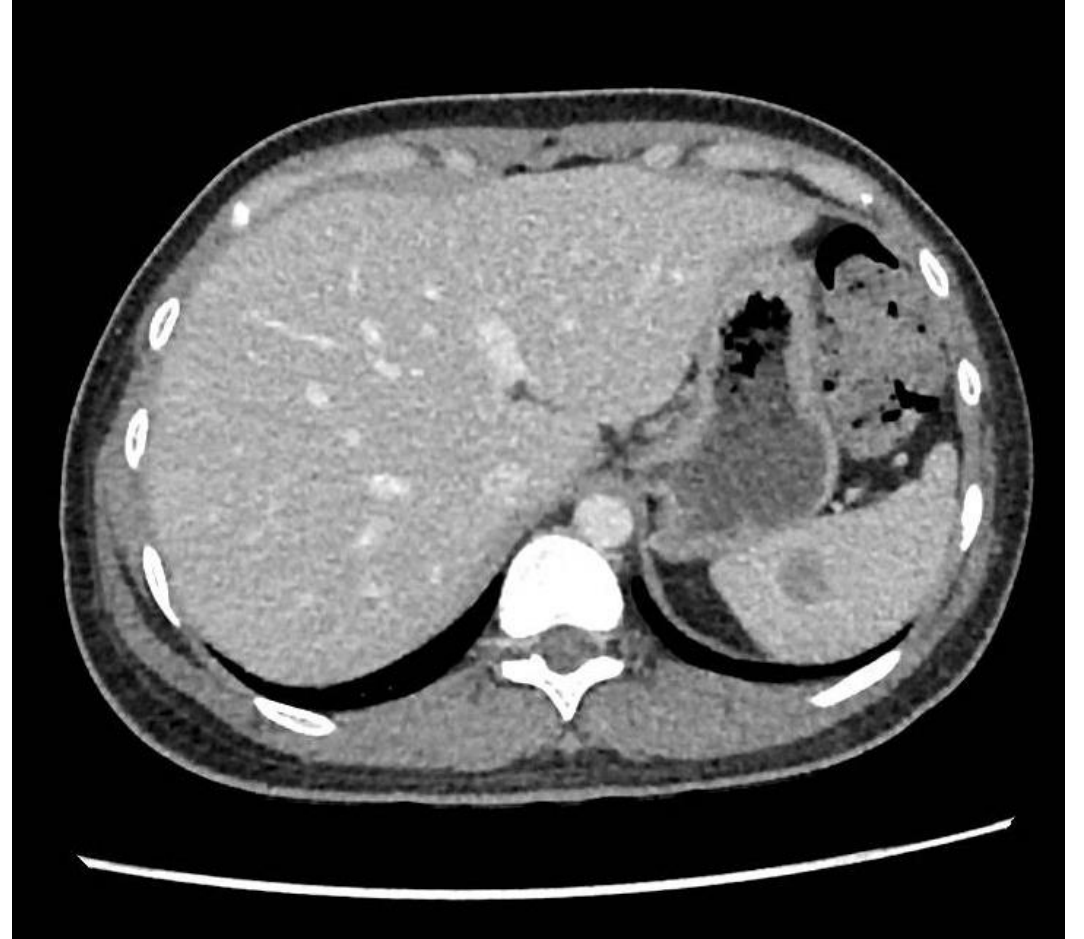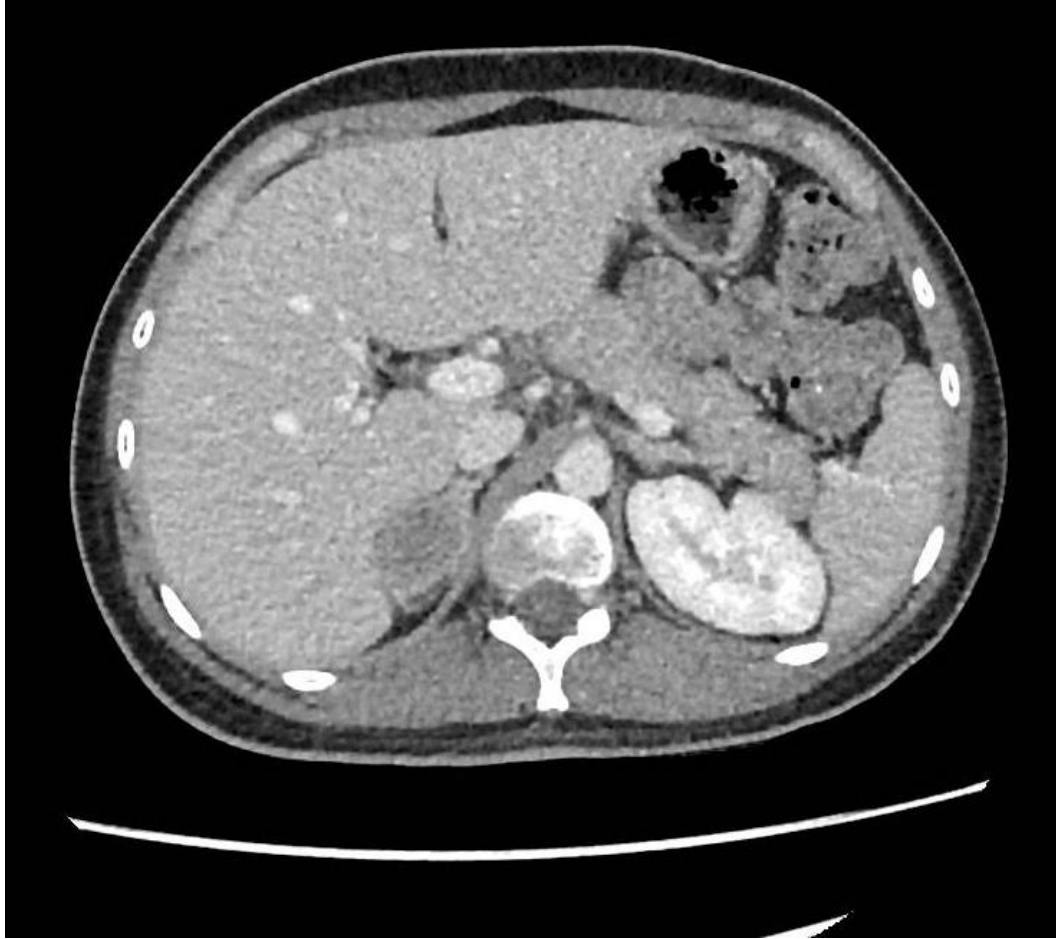Infectious Diseases and General Medicine Advanced Trainee
Royal Adelaide Hospital & Royal Darwin Hospital

- Written informed consent obtained
- Nil conflicts of interest

Case Presentation

- 27-year-old man from Indonesia
- Worked in agriculture
- No past medical history
- Presentation: Hiccups, fever and ataxia
- **New diagnosis advanced HIV**
 - Viral load 82,100 copies/mL; CD4 12cells/ μ L
 - Commenced on bicittegravir / tenofovir alafenamide / emtricitabine
- Complicated by opportunistic infections:
 - Cerebral toxoplasmosis
 - Oral candidiasis
 - Cytomegalovirus viraemia



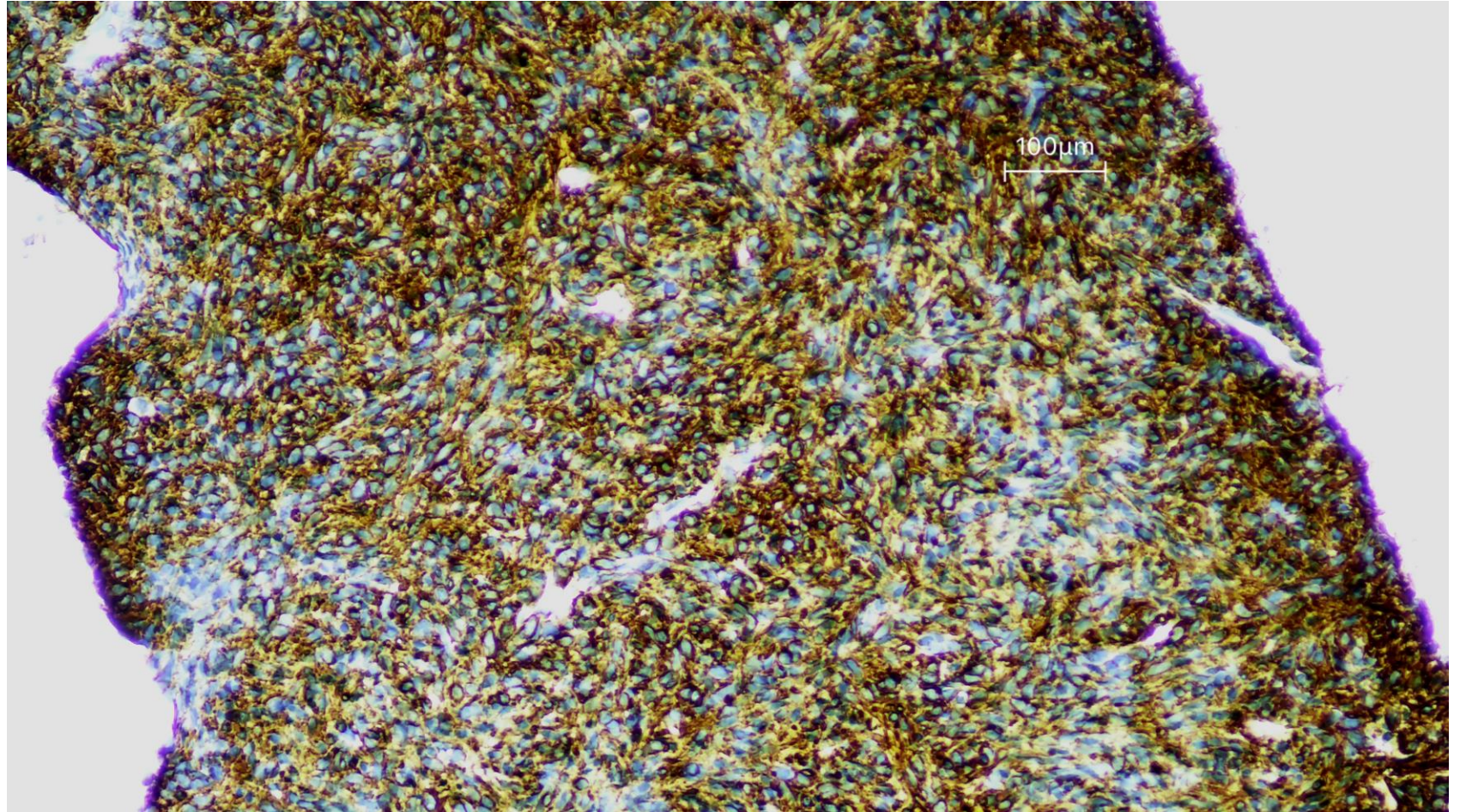
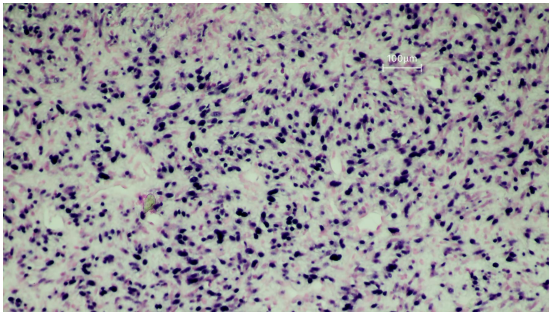
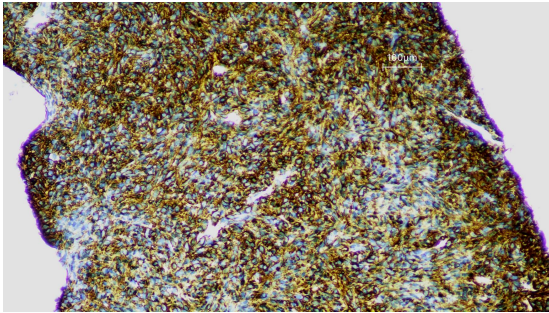
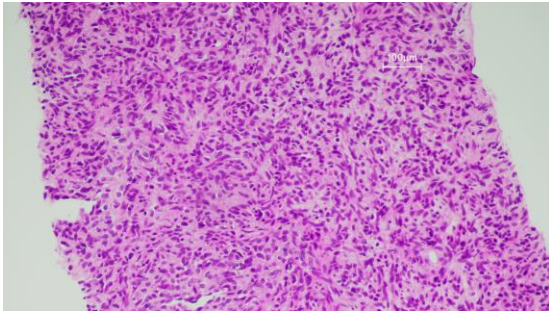


Investigations

- Blood cultures, serum cryptococcal antigen and histoplasma serology negative
- EBV serology: IgM- / IgG+
- EBV NAT: Detected, <1000 copies/mL

Core biopsy of R adrenal lesion

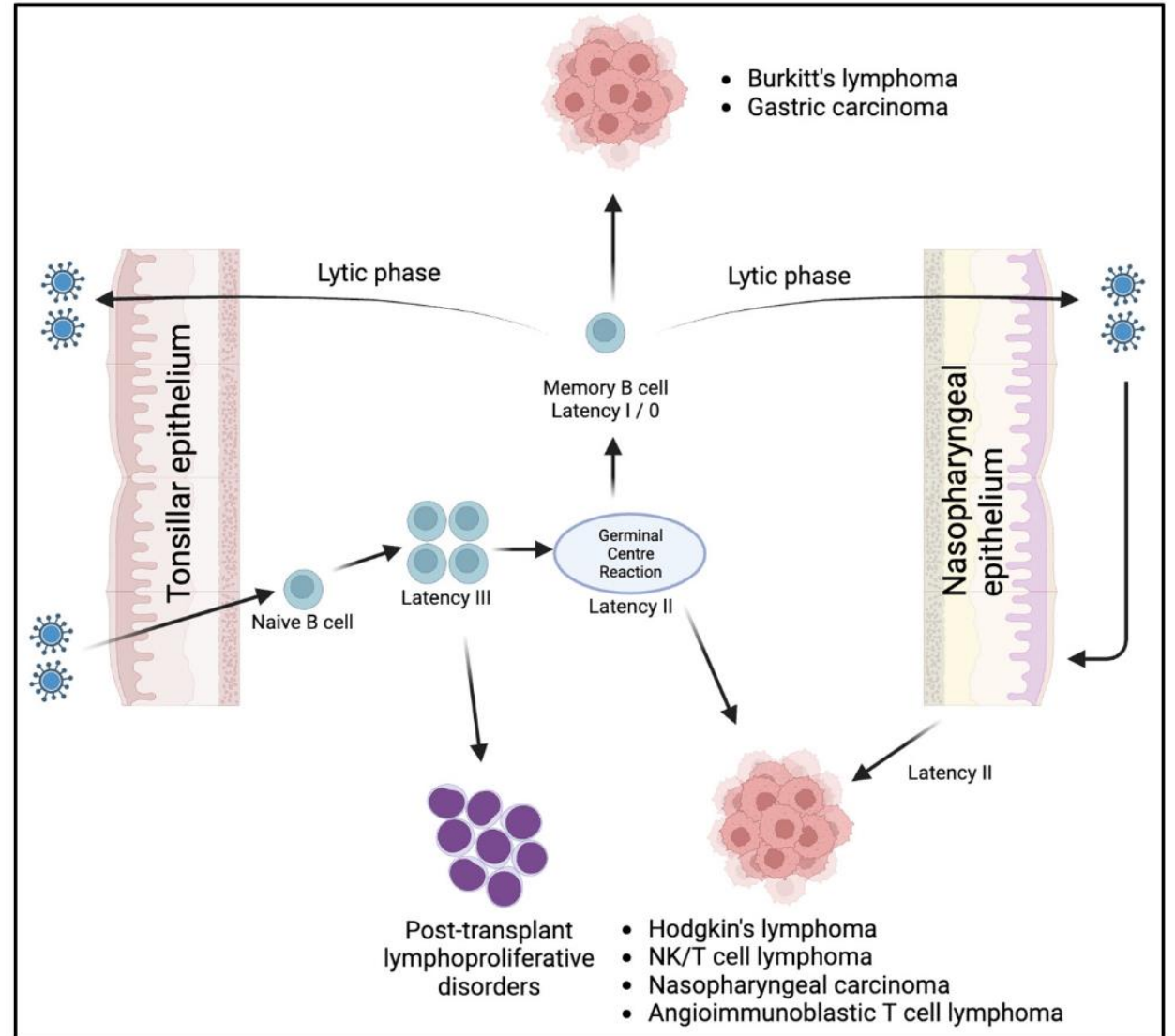
- Culture:
 - Bacterial – Nil growth
 - Mycobacterial – AFB smear negative, nil growth
 - Fungal – Nil fungal elements seen, nil growth
- Histology:
 - “Spindle cell lesion with smooth muscle actin positivity by immunohistochemistry”



With thanks to Dr Alexandra Jolley

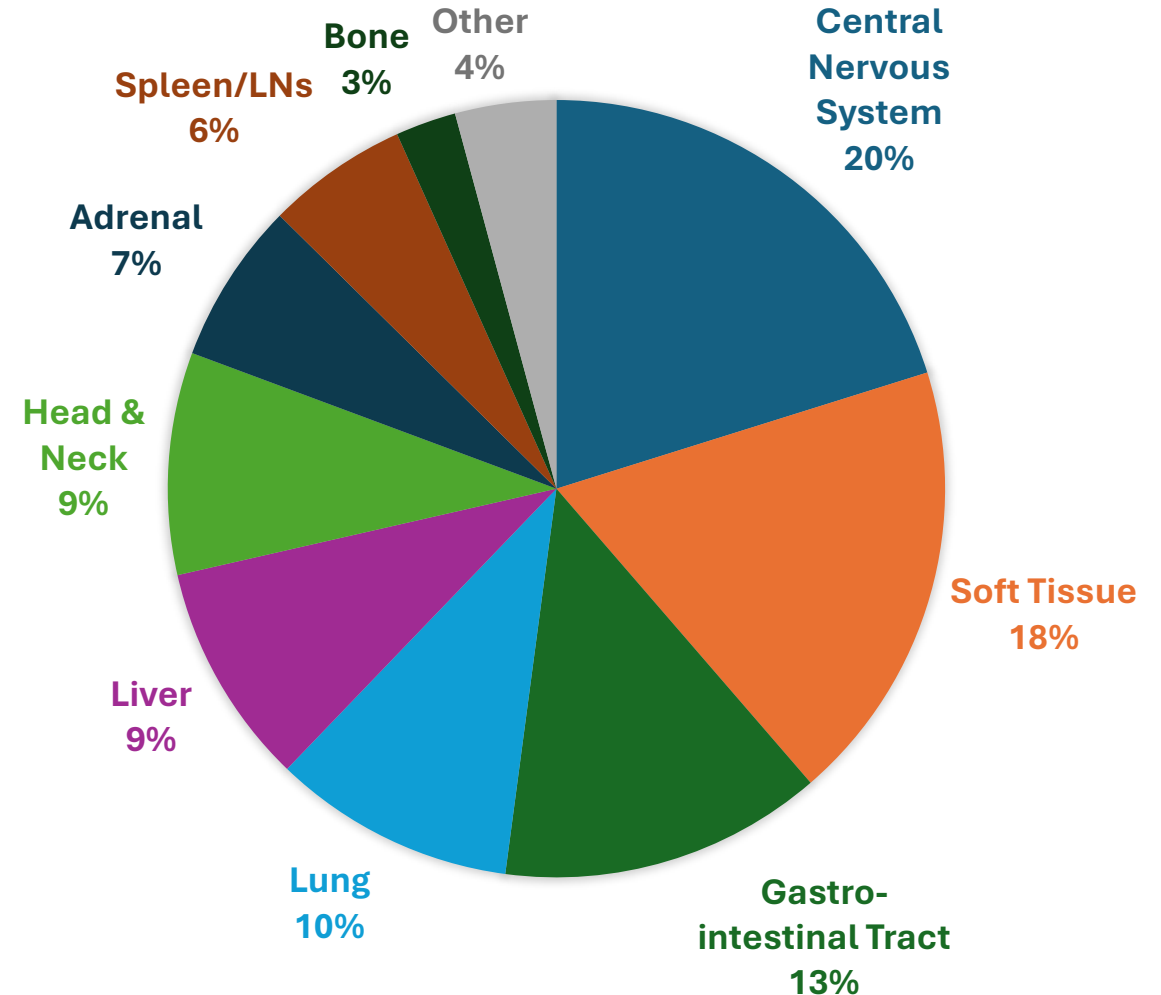
EBV – Back to the Beginning

Herpes Virus	Subfamily
HSV-1 (HHV1)	Alpha
HSV-2 (HHV2)	Alpha
Varicella-zoster virus (HHV3)	Alpha
Cytomegalovirus (HHV5)	Beta
HHV6	Beta
HHV7	Beta
Epstein-Barr virus (HHV4)	Gamma
Kaposi sarcoma-associated herpesvirus (HHV8)	Gamma



EBV-Associated Smooth Muscle Tumours

- Rare neoplasms in **immunocompromised hosts** (HIV, post-transplant, congenital)
- Data limited to case reports/series (n ≈ 100 in HIV)
- Any age / any organ¹
- Multifocal primaries²

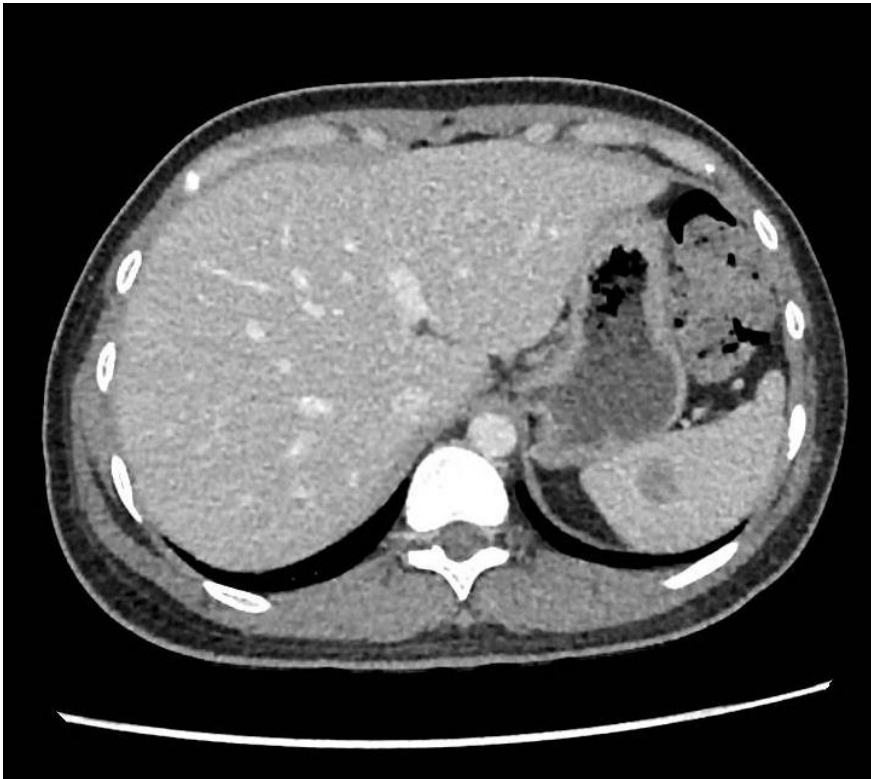

EBV-Associated Smooth Muscle Tumours

- Pathogenesis
 - EBV entry: CD21 on smooth muscle cells vs lymphocyte fusion
 - EBV LMP2A → Akt-mTOR activation → proliferation
- WHO 2020: “Intermediate-grade” → between leiomyoma & leiomyosarcoma

Management

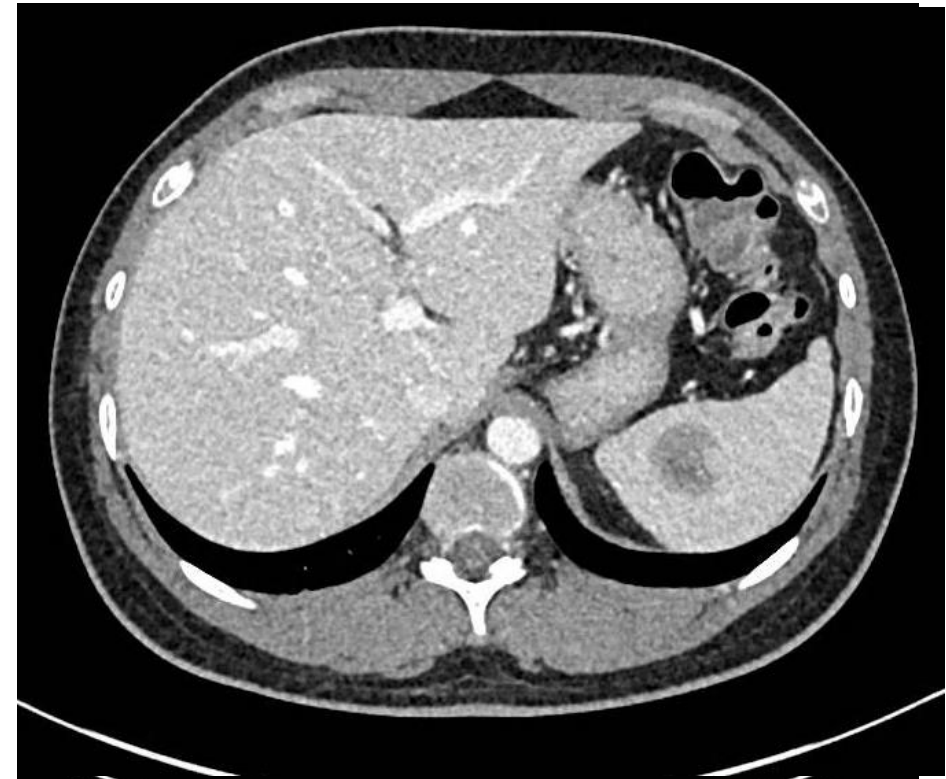
- Treatment paradigms:
 - **Immune reconstitution** (antiretrovirals, ↓immunosuppression, stem cell transplant)
 - Surgery (symptomatic / solitary lesions)
 - Limited role: chemotherapy / radiotherapy
 - Emerging: mTOR inhibitors, EBV-specific T-cell therapy
- Prognosis historically determined by HIV control and opportunistic infections



At diagnosis

HIV viral load 82,100 copies/mL

CD4 count 12 cells/ μ L



After 19 weeks of antiretroviral therapy

HIV viral load <20 copies/mL

CD4 count 50 cells/ μ L

?Immune reconstitution inflammatory syndrome (IRIS)

- Differential diagnoses:
 - IRIS, disease progression, second pathology
- Exaggerated and dysregulated cellular immune response to an antigen after commencement of anti-retrovirals¹
 - Infection, malignancy (Kaposi sarcoma, lymphoma), autoimmunity
- 2 cases of possible IRIS in EBV-SMT associated with HIV^{2,3}
- No consensus definition

Conclusion

- EBV-associated smooth muscle tumour should be considered in the differential of mass lesions in people living with HIV
- Treatment is predominantly immune reconstitution +/- surgery
- Lesion progression despite immune reconstitution may reflect an IRIS-like phenomenon – further research needed

Acknowledgements

- Our patient whose lived experience contributed to our learning
 - RAH Infectious Diseases Multidisciplinary Team including A/Prof Emily Rowe, Dr Brendan Kennedy, Dr Matt Roberts
 - Other RAH teams: Neurosurgery, Medical Oncology, Immunology, Dermatology, Ophthalmology, Gastroenterology, Radiology
 - Dr Alexandra Jolley (RAH Pathology)
 - Prince of Wales Hospital Infectious Diseases Unit
-
- Email: michael.riceman@sa.gov.au



Health
Central Adelaide
Local Health Network