



复目と右腕



- **G**reat surgeon

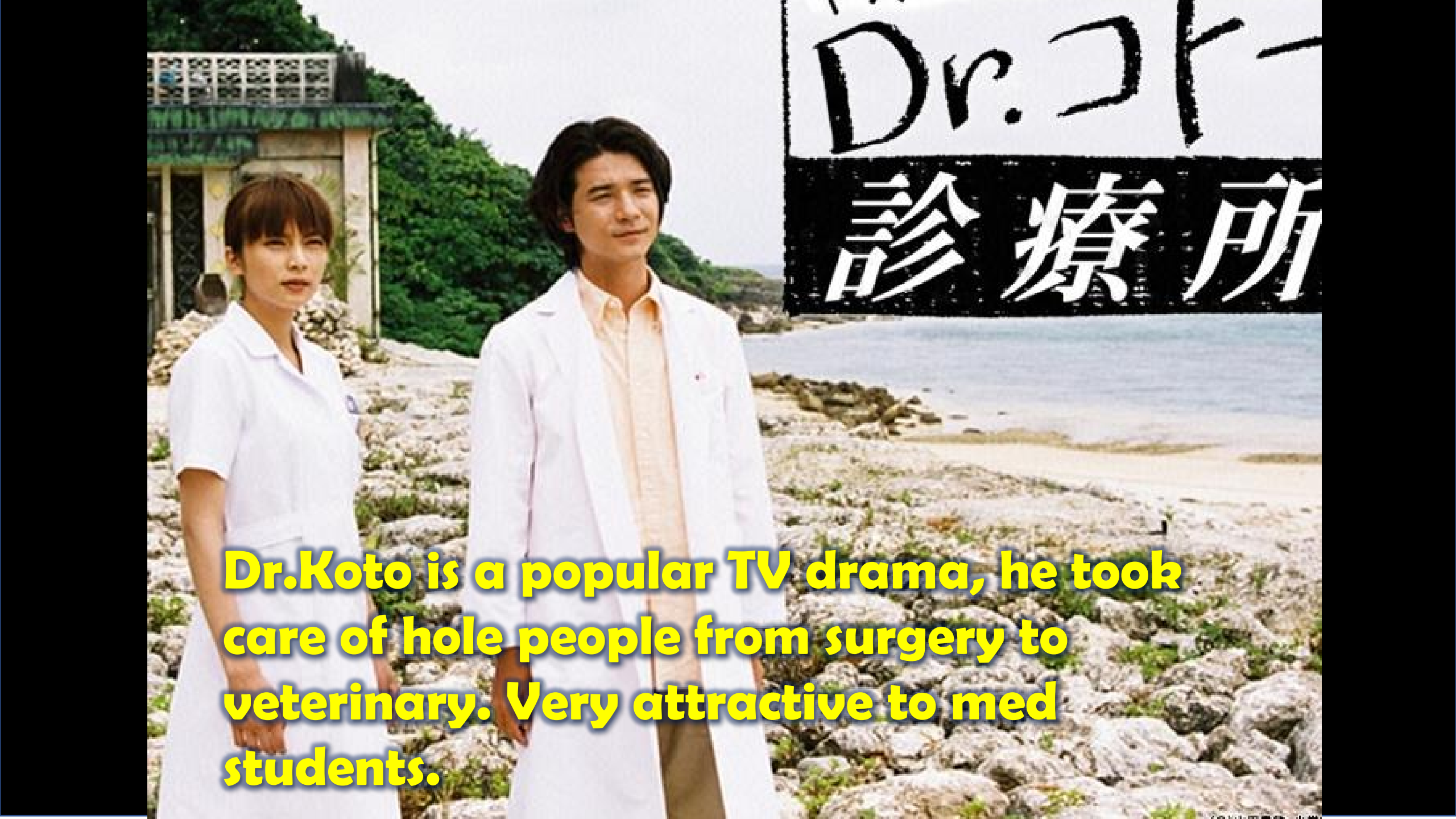
- **40** years

- **P**ioneer of Rural GP

# Doctor Stories

from the Island Journals of the Legendary "Dr. Koto"



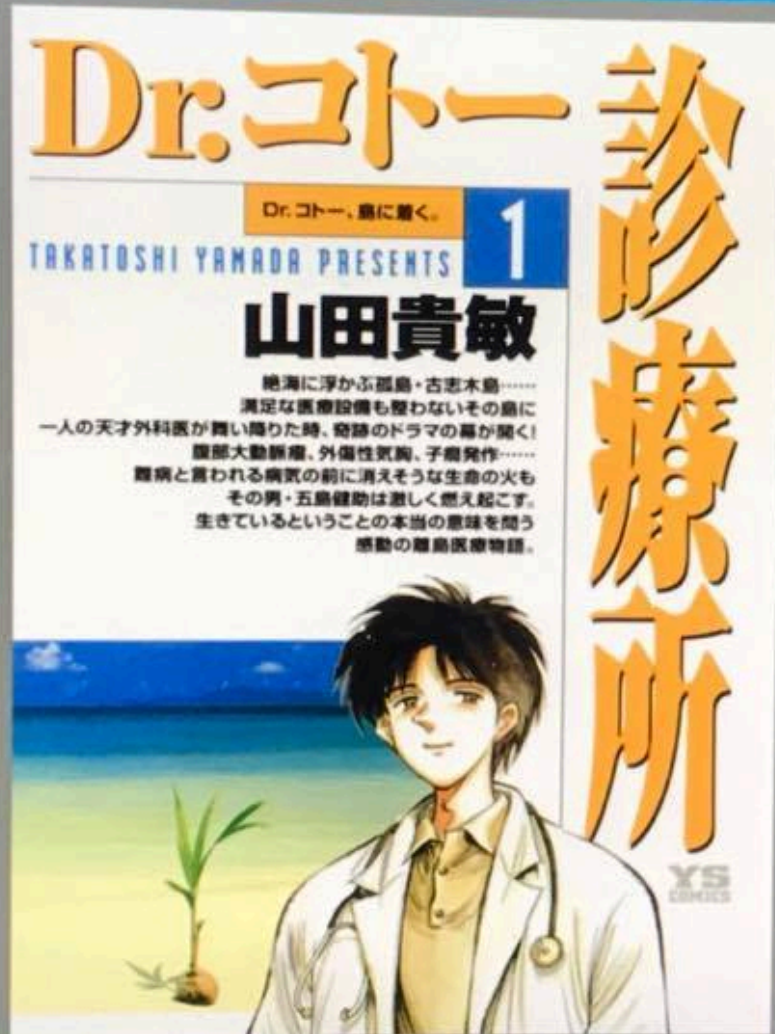


Dr. Koto

診療所

**Dr.Koto is a popular TV drama, he took care of hole people from surgery to veterinary. Very attractive to med students.**

# On the way to Melbourne, on the JAL flight



ページ  
1 / 209



コントロール

終了

次へ 前へ

拡大表示


メインメニュー





大人でも  
これくらいの  
大きさは  
珍しい。

しかも一部は  
破れて、膿が  
出ています。  
気絶するような  
激痛だったろうに、  
タケヒロくんは  
よく我慢しました。



よし、  
終わったぞ！



先生、  
血圧下がって  
ます！

大丈夫なのか、  
タケヒロは！！

腰痛が出る、  
生食で洗浄を！！



ハア  
ハア  
ハア



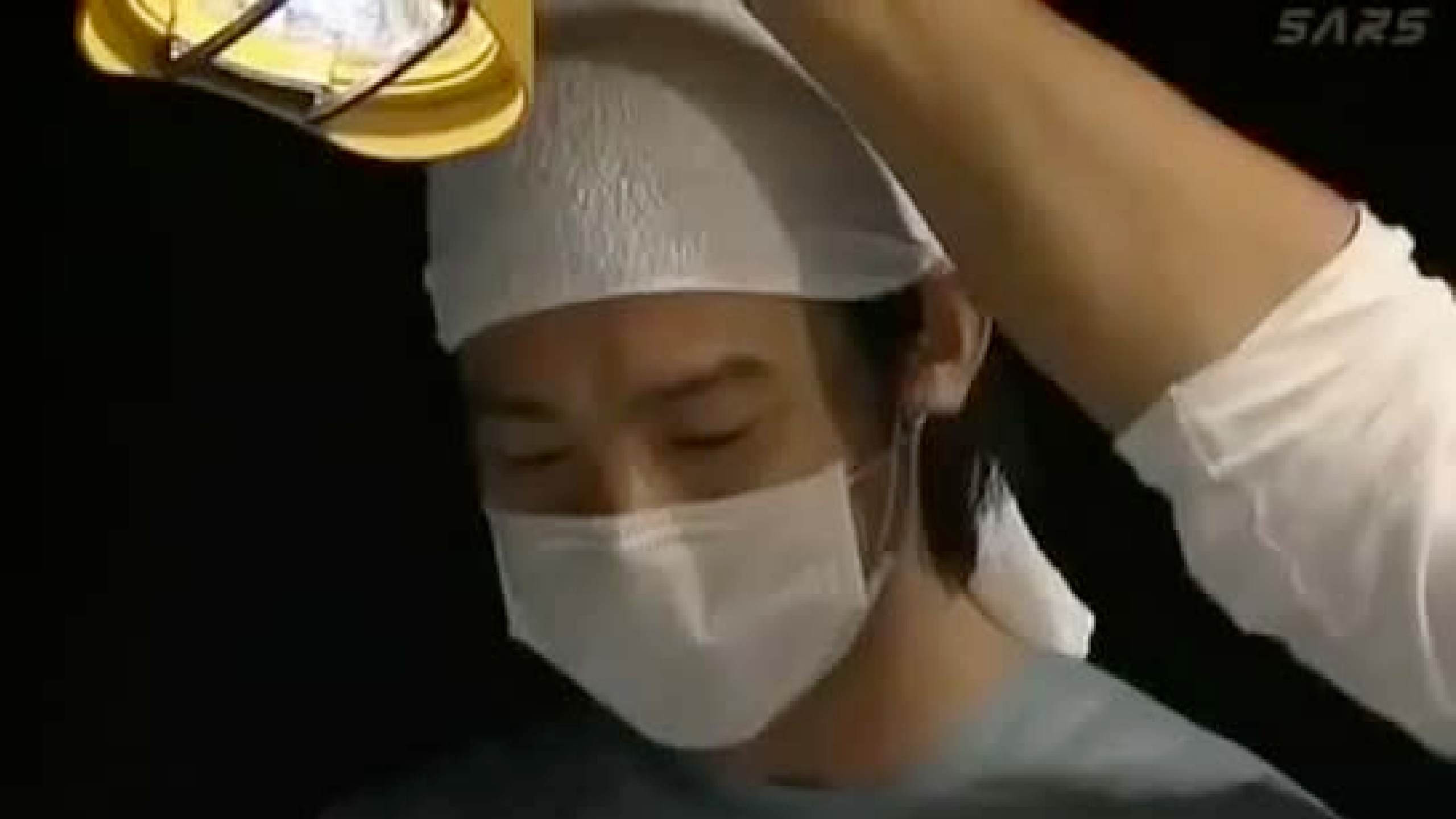タケヒロくん、  
洞窟へ一人で行って  
コントローラー  
取って来たんだってな。

もう少し  
だから  
がんばろうな。

すごいな、  
ほくには絶対  
無理だよ。

うん。

よし、  
取れた！！

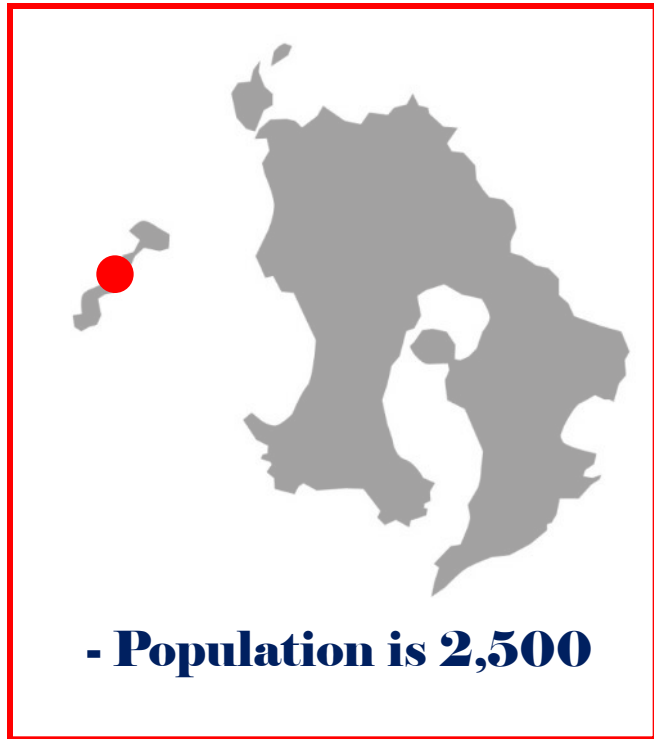




# **An Interesting Island Medicine**

**Dr. Kenjiro Setoue  
76-year-old surgeon**

# **Koshiki Island**





**My arrival was in 1978**  
**5 hours from the mainland by ferry**



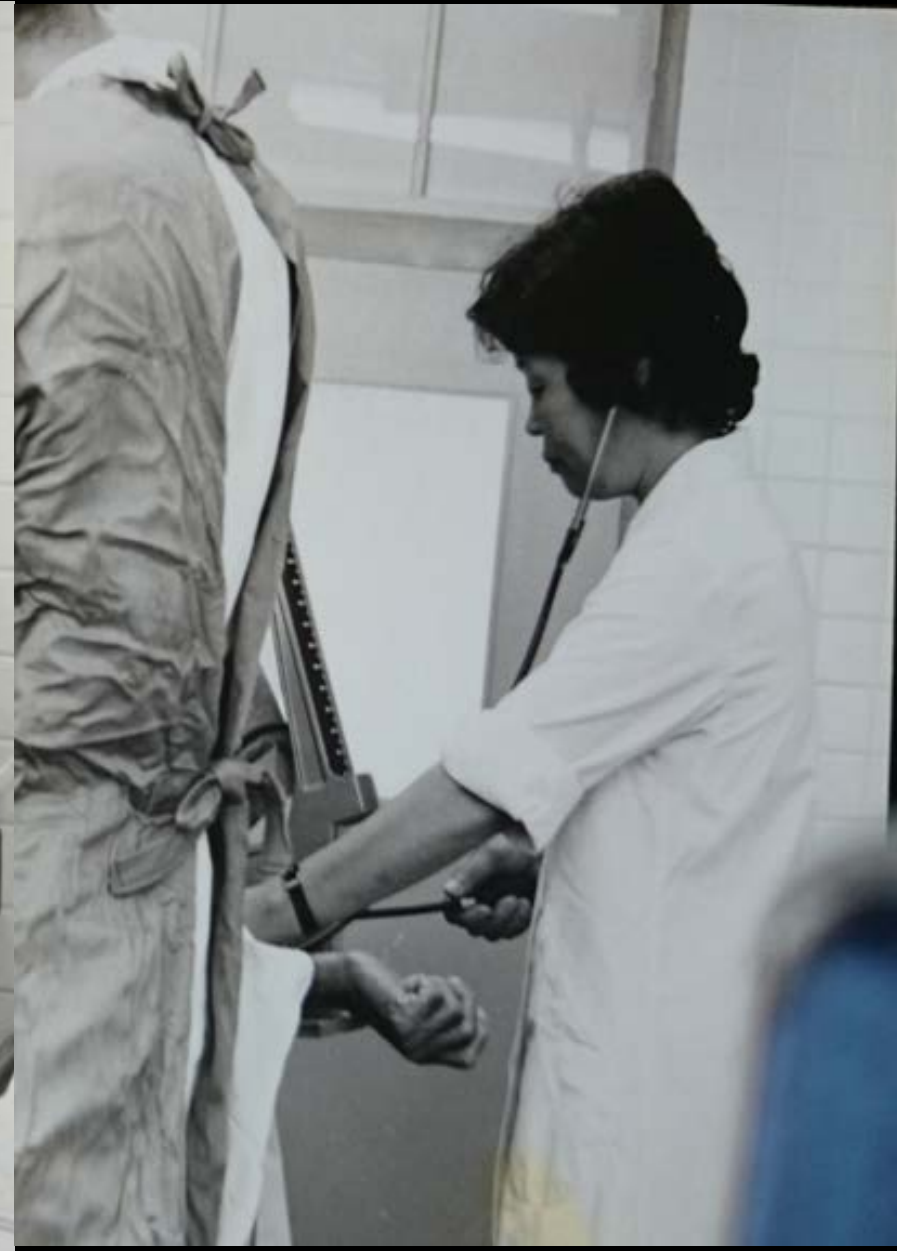

# Teuchi Village

**Residents are proud of  
being descendants of Samurai.**




# Only two nurses at the beginning

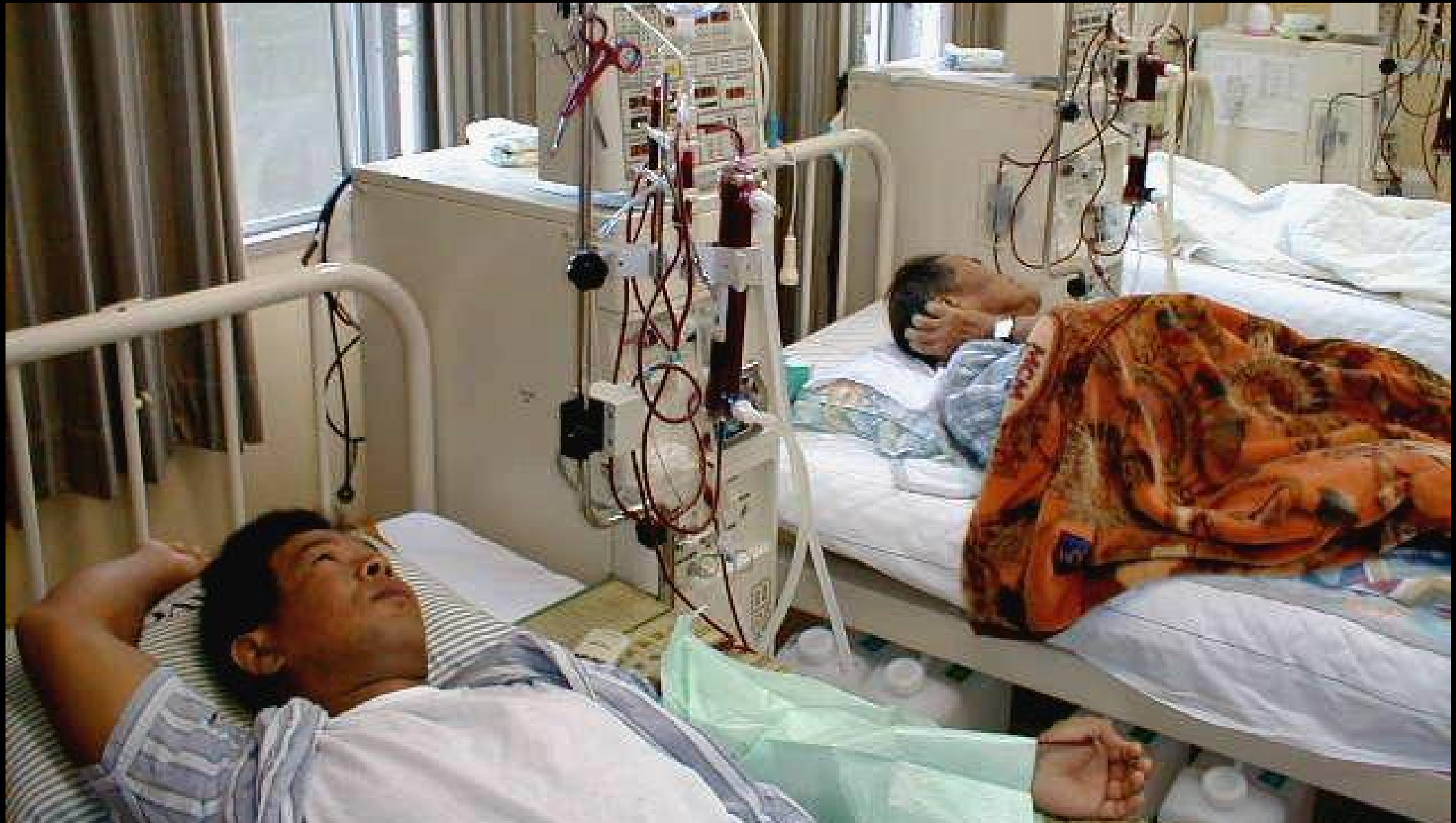

# Home Visit

- Families used to live together



# Hemodialysis since 1990

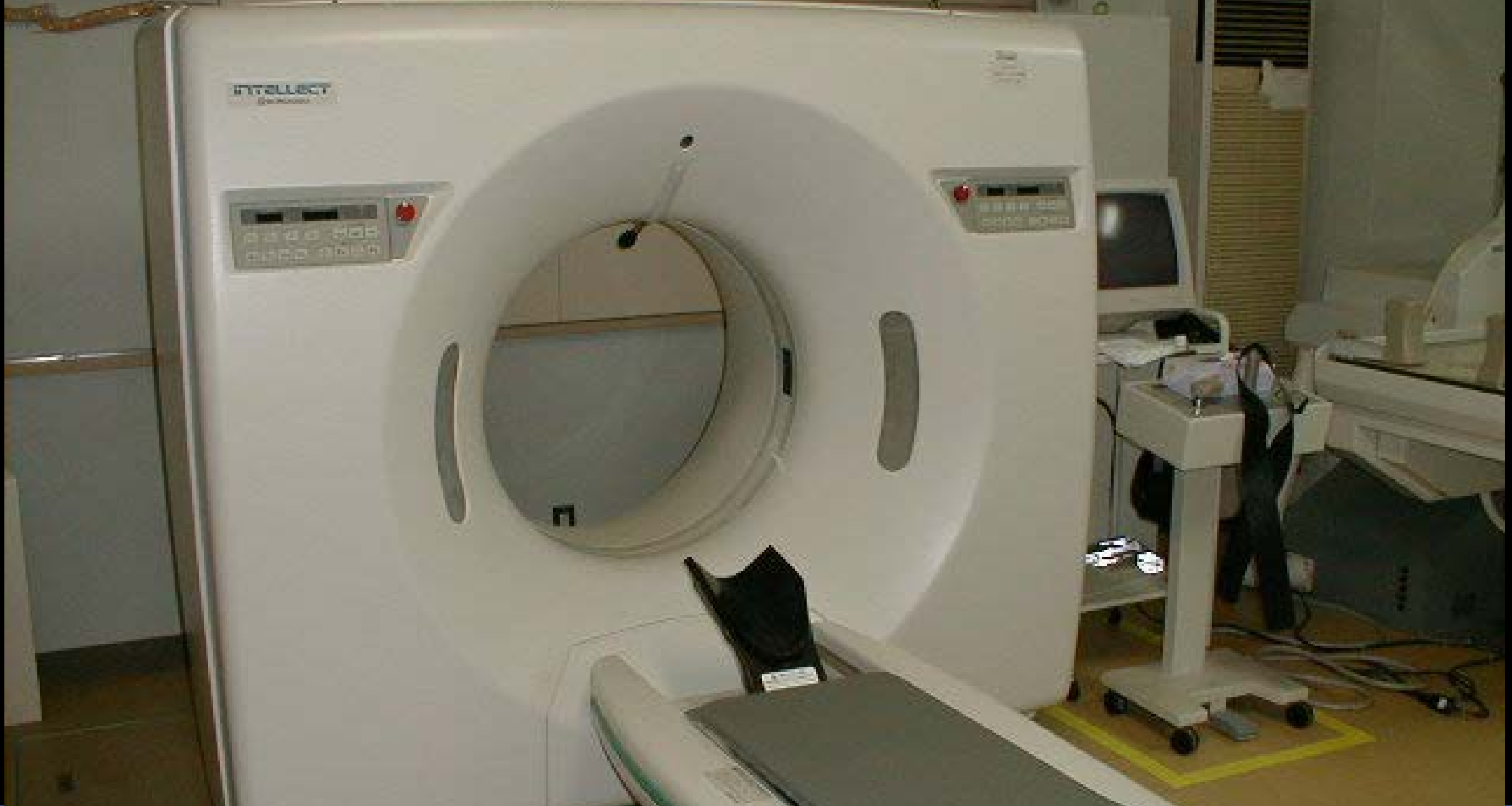



# HD patients' quality of life improved



# CT since 1996

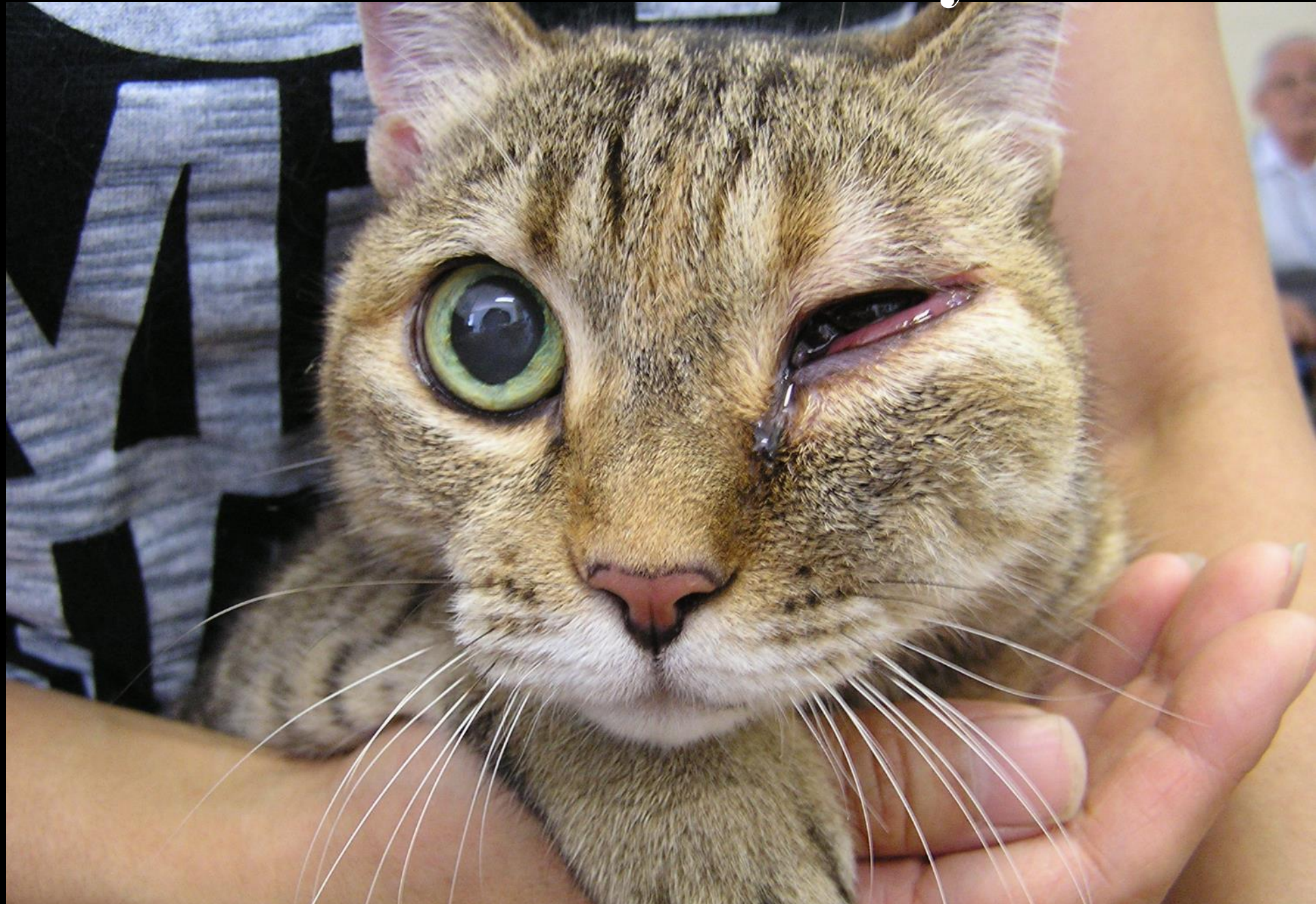

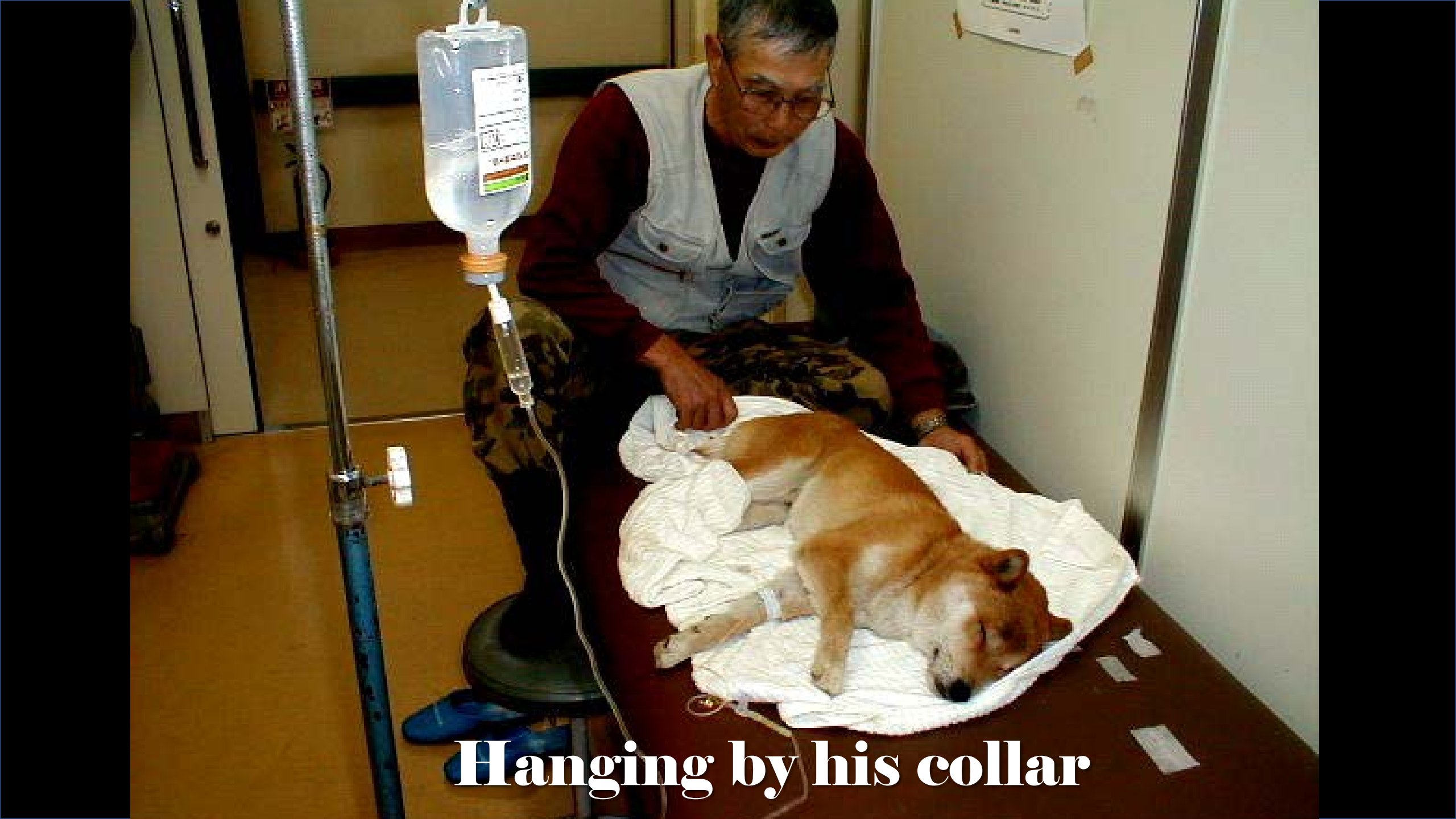**Scope of Practice**

**Veterinary**



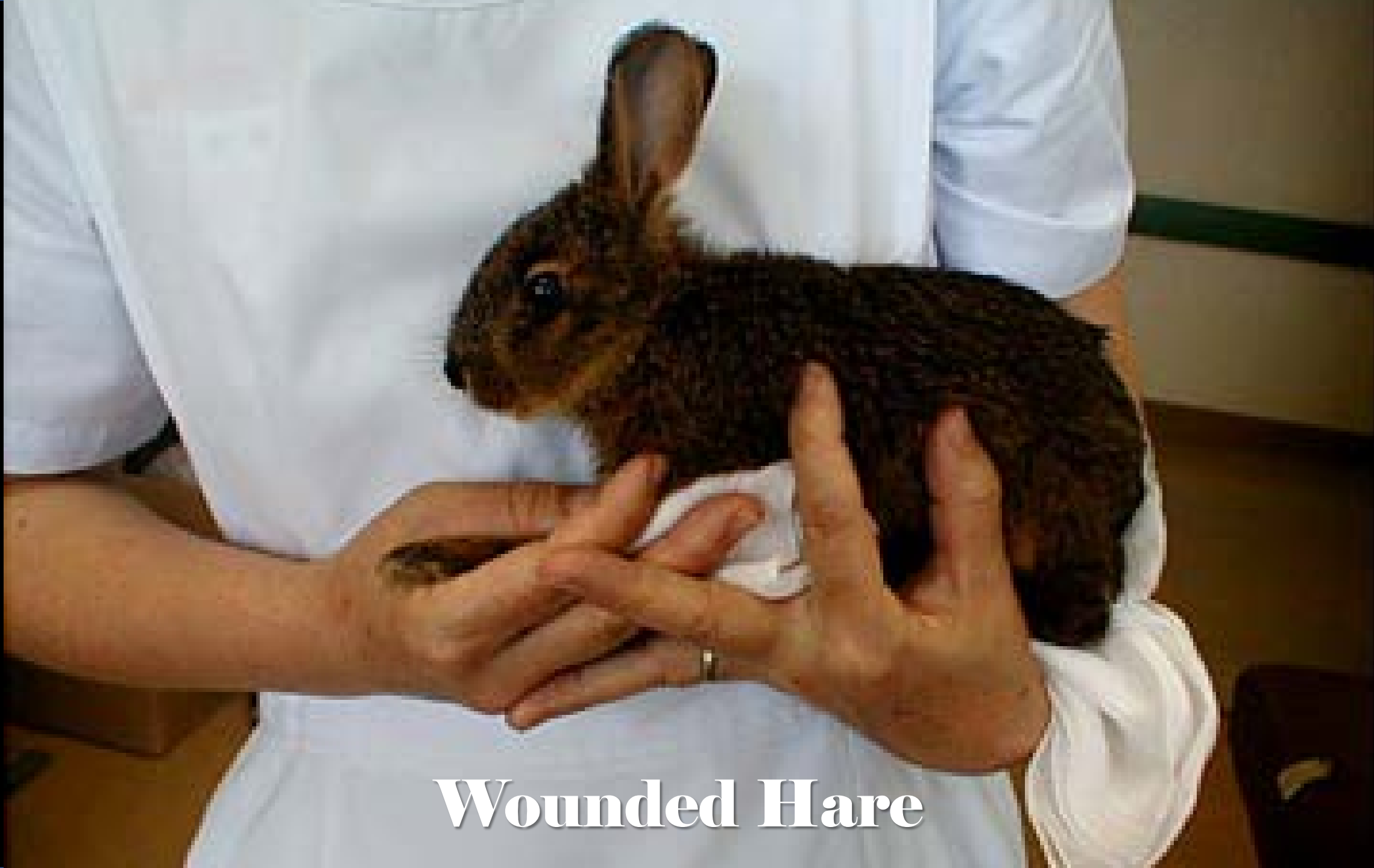# Abscess in left eye





**Hanging by his collar**



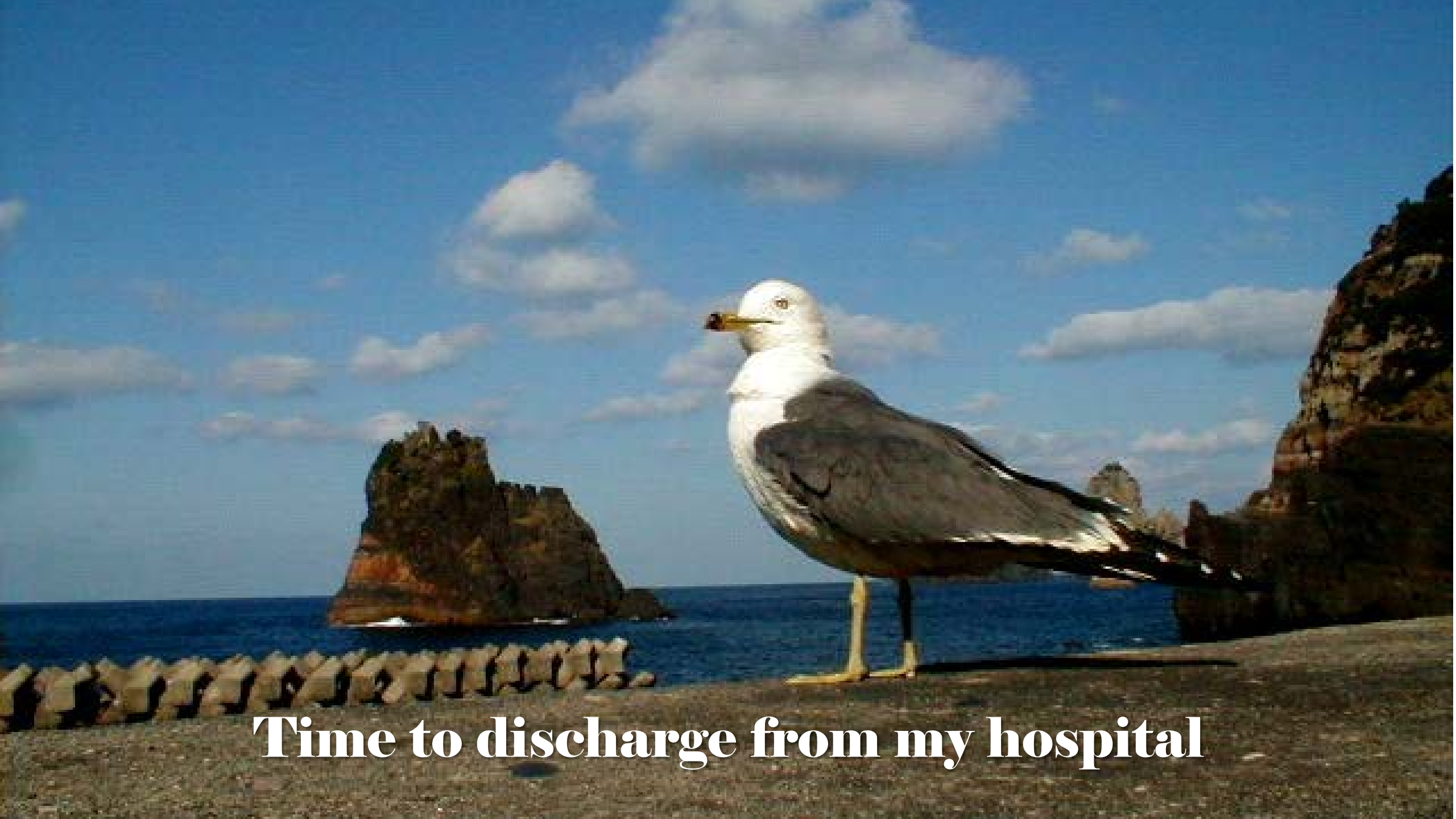


**Wounded Hare**





**A seagull was admitted with broken wings**



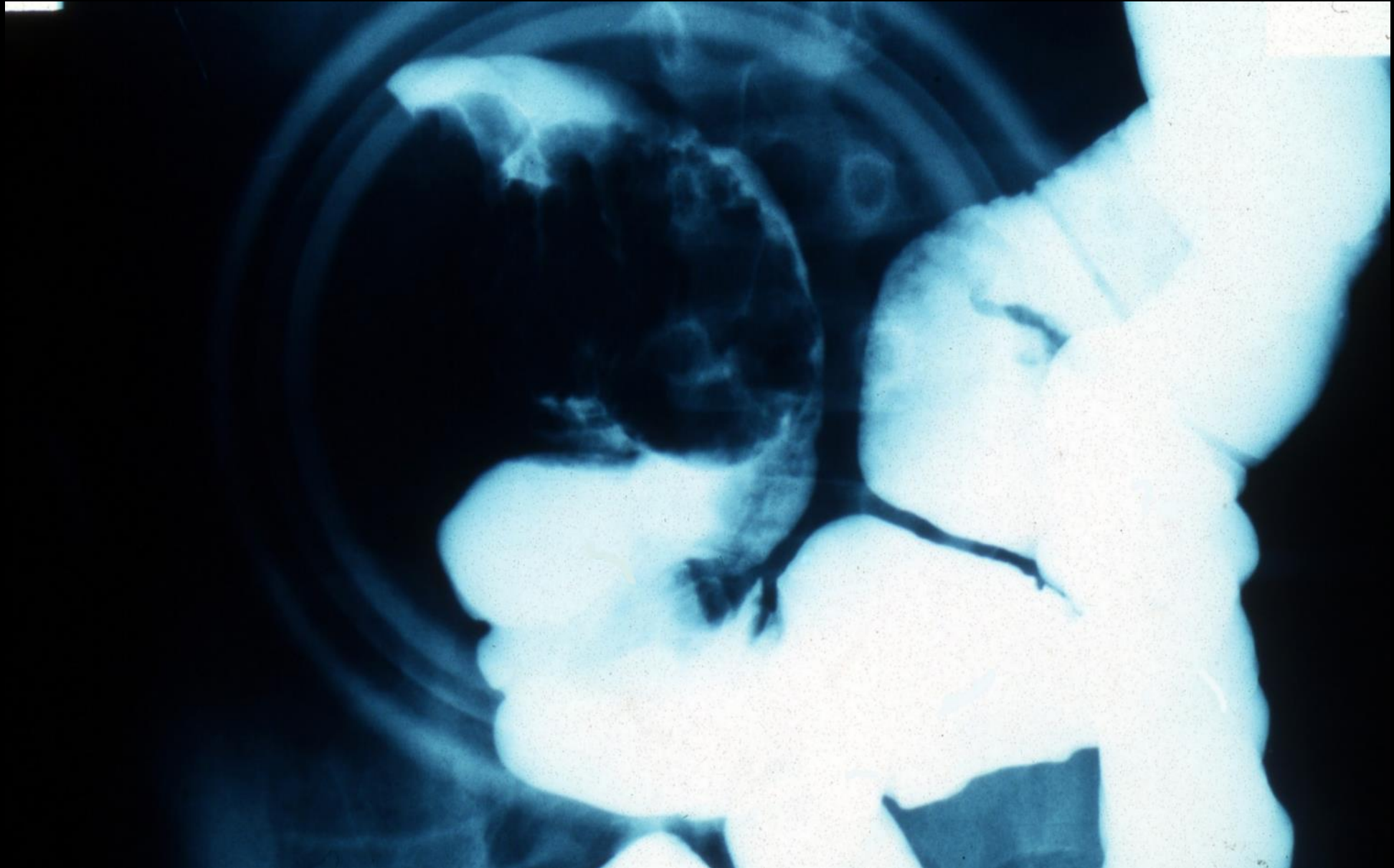
**Time to discharge from my hospital**

**Scope of Practice**

**Pediatrics**



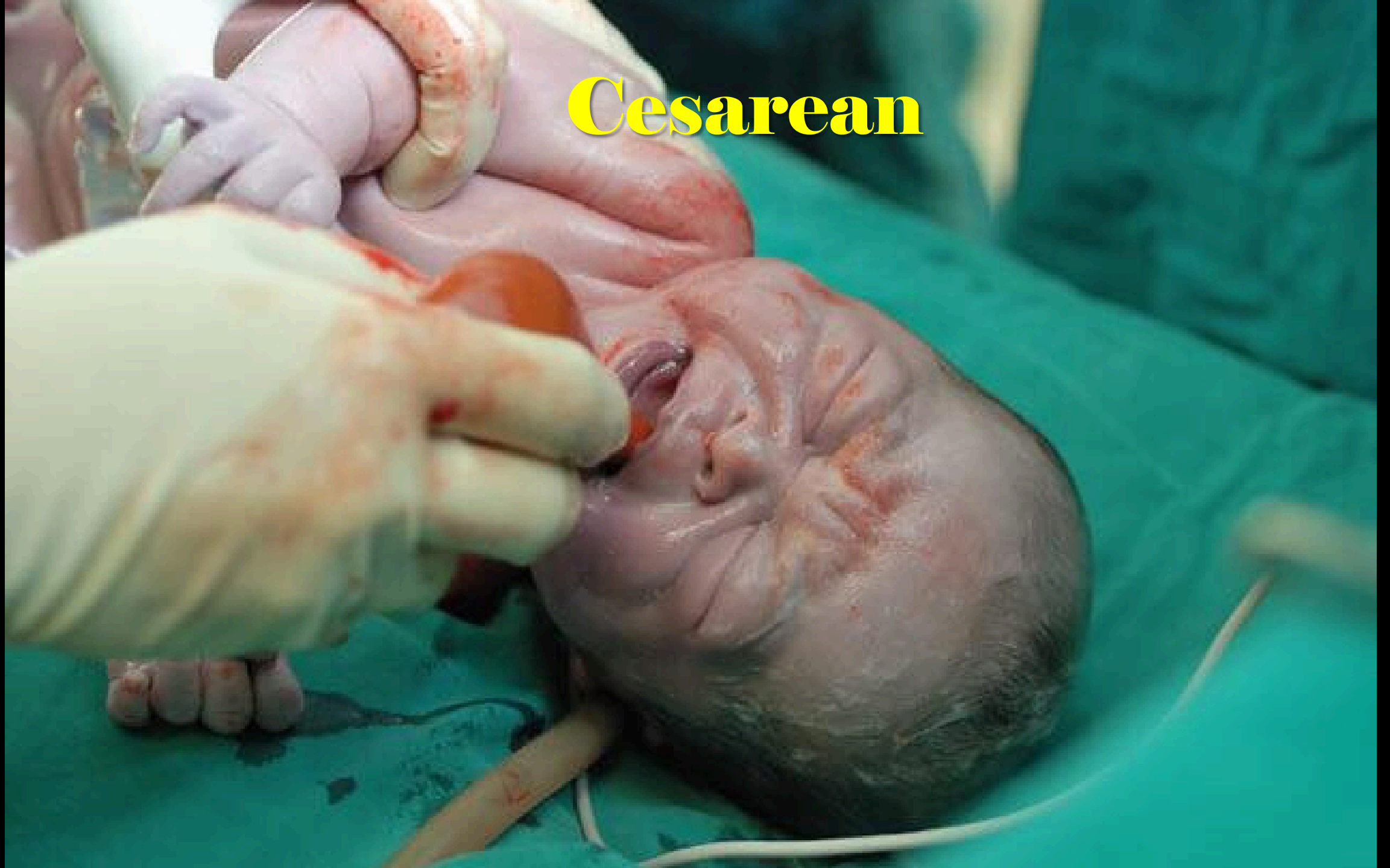# Invagination (4-year-old)



**Scope of Practice**

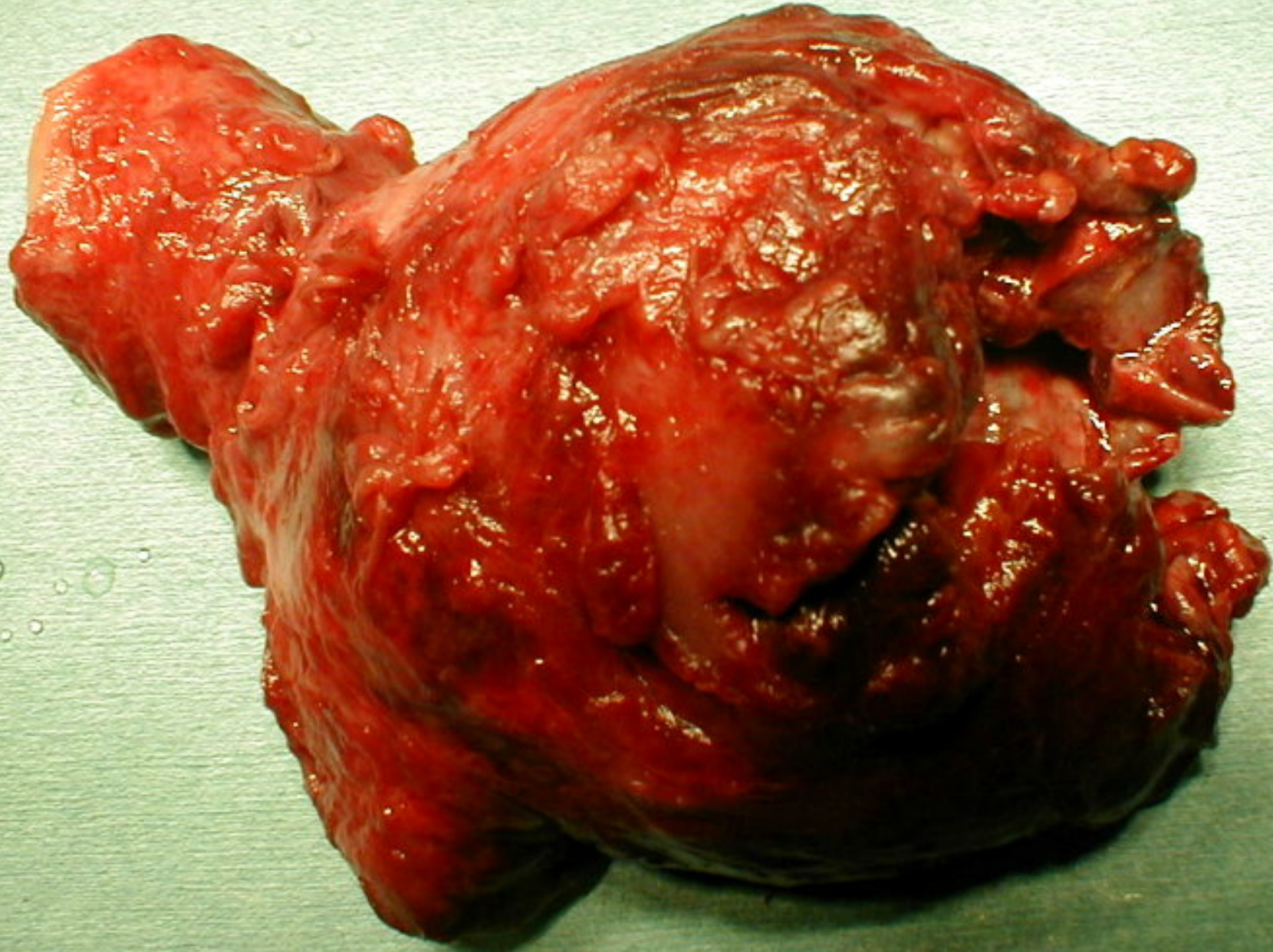
**Obstetrics and Gynecology**

# Cesarean



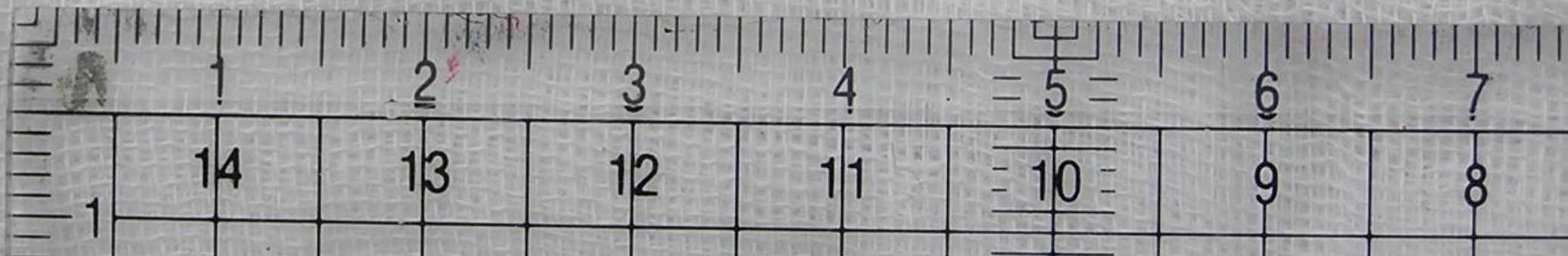
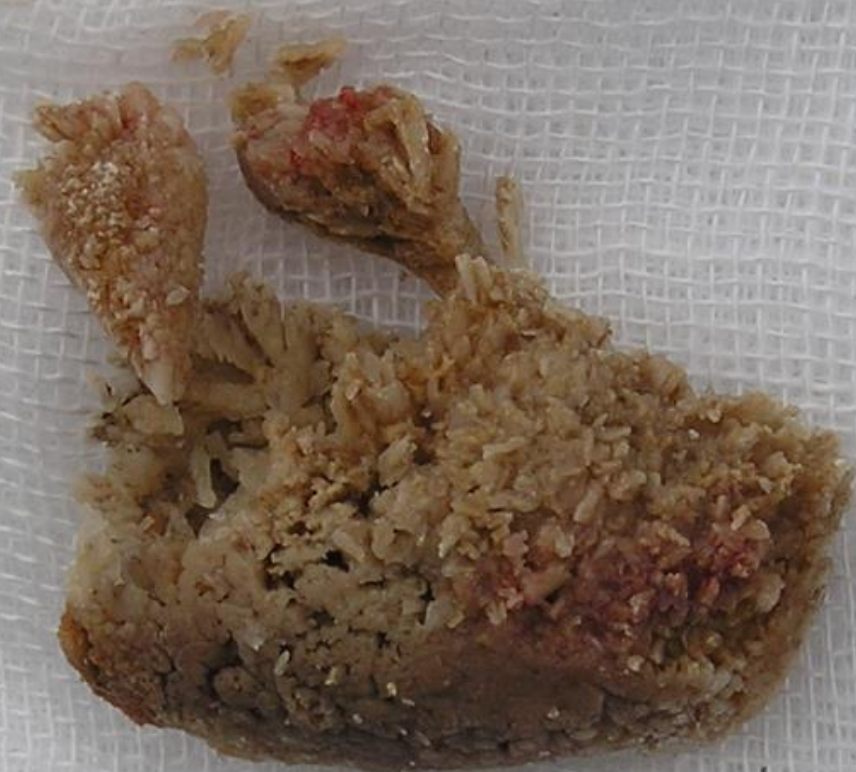

**pyometra**






# Vagina stone (102-year-old)



**Scope of Practice**

**Parasite Medicine**





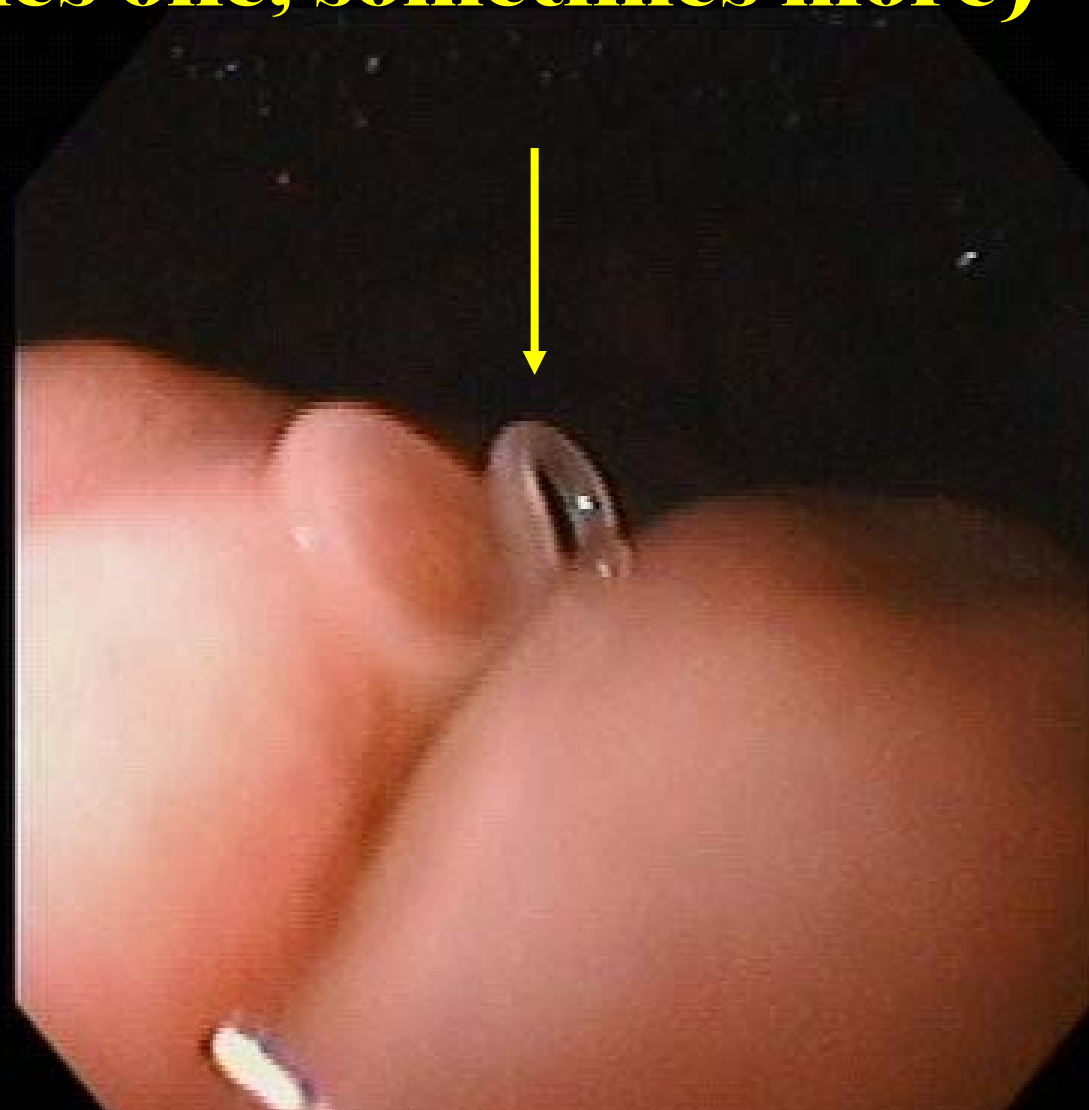
**Rash caused by eating sashimi  
(Anisakis)**

# Anisakis

975 (sometimes one, sometimes more)  
M 53  
S27/04/05

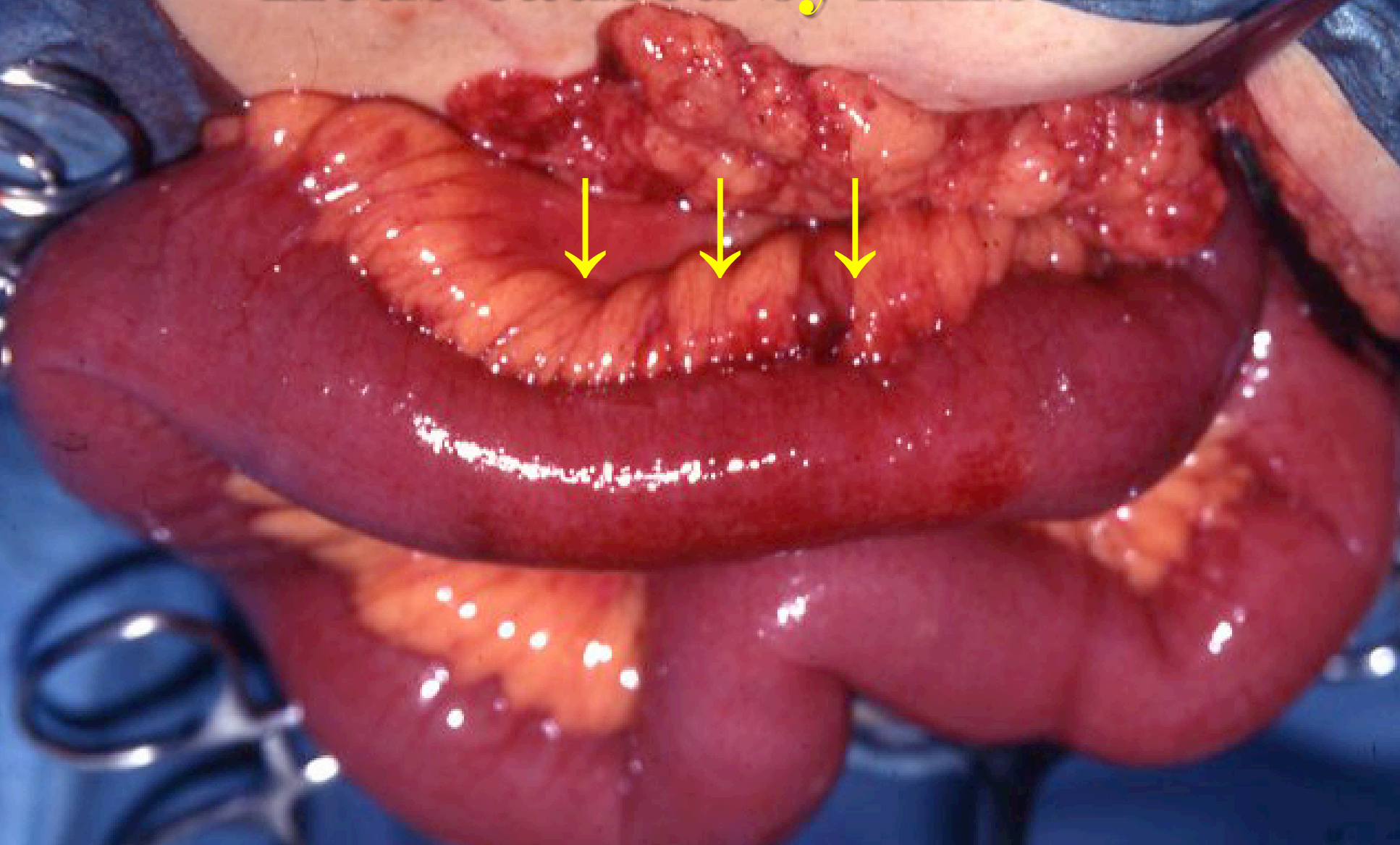
2005/11/11  
10:16:37

SCV-----99



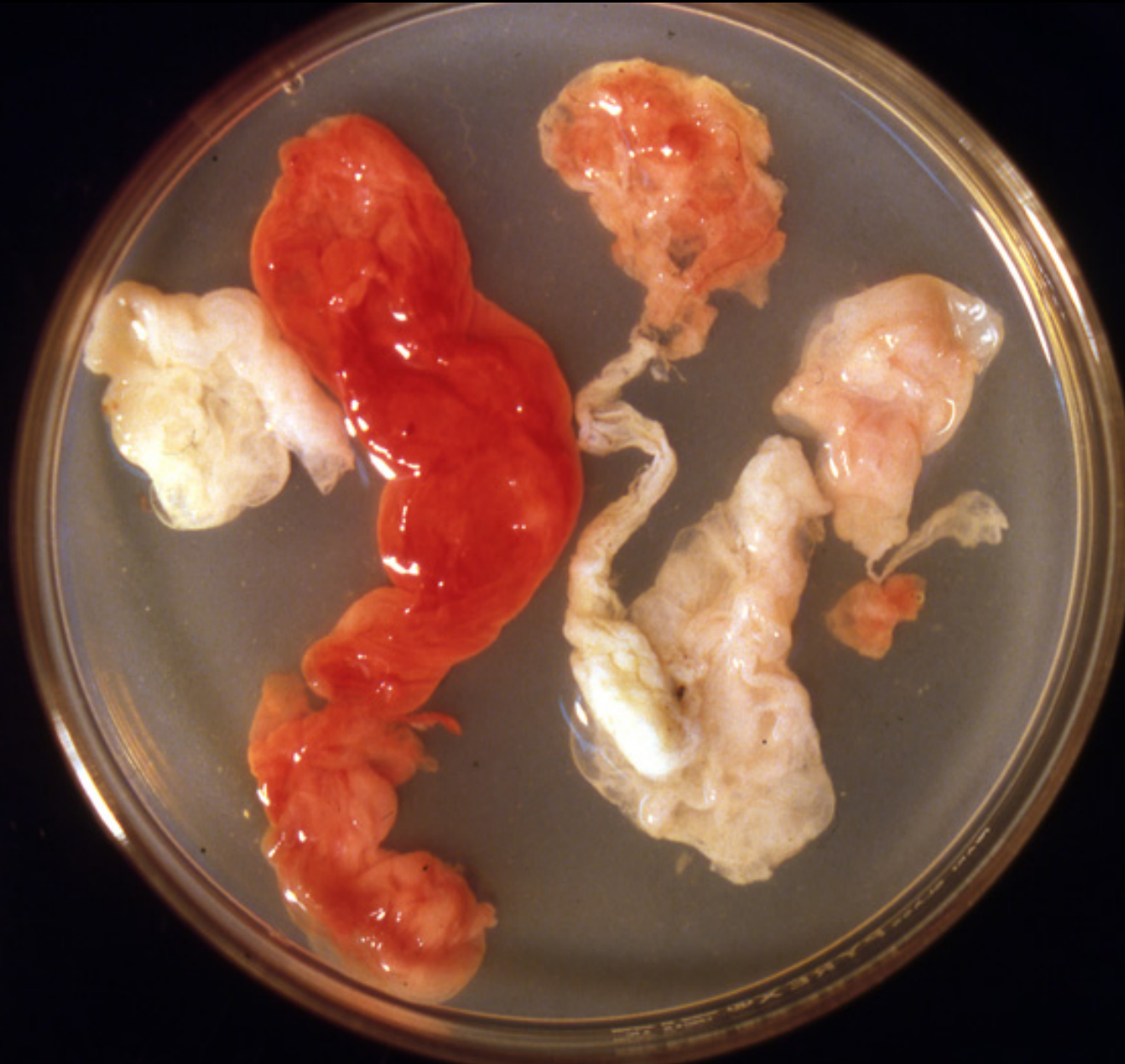

# Ileus caused by Anisakis






# Filaria found in urine






# Living filaria found in urine, first discover in the world





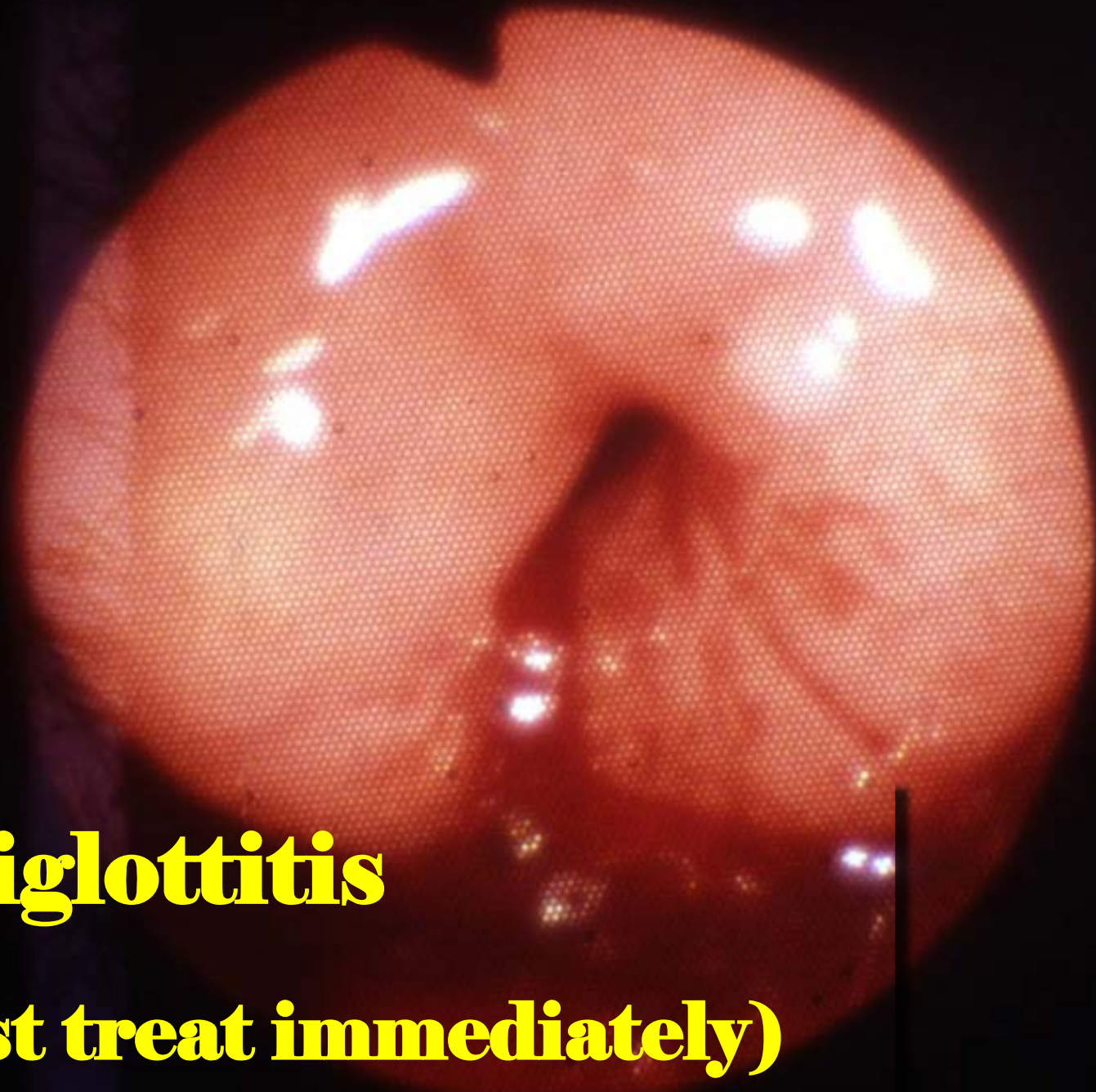
# Tapeworm





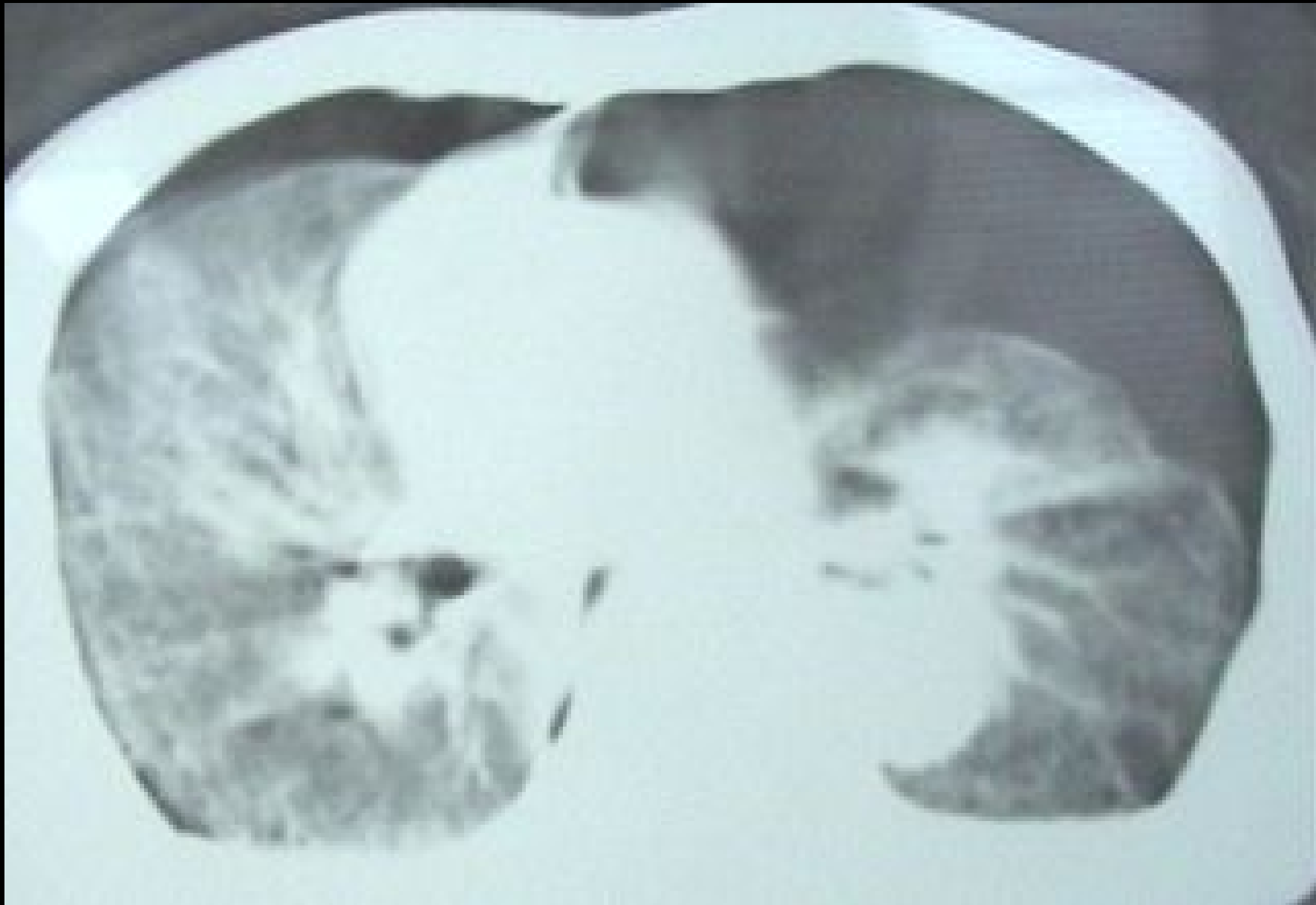
## **Scope of Practice**

**Emergency medicine**  
**- the highest priority**



**Epiglottitis**  
**(must treat immediately)**

# Bilateral pneumothorax



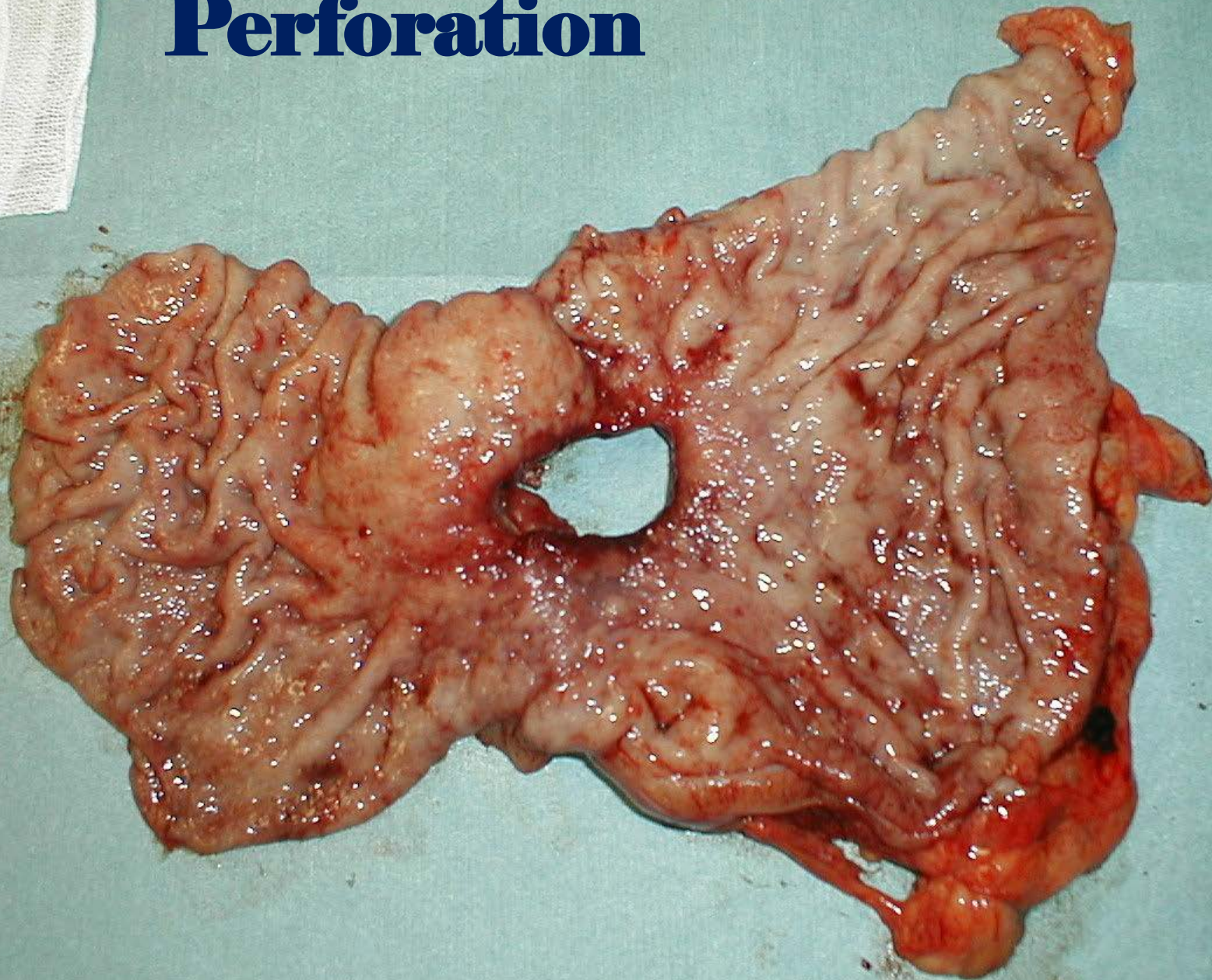## **Scope of Practice**

# **Surgery**

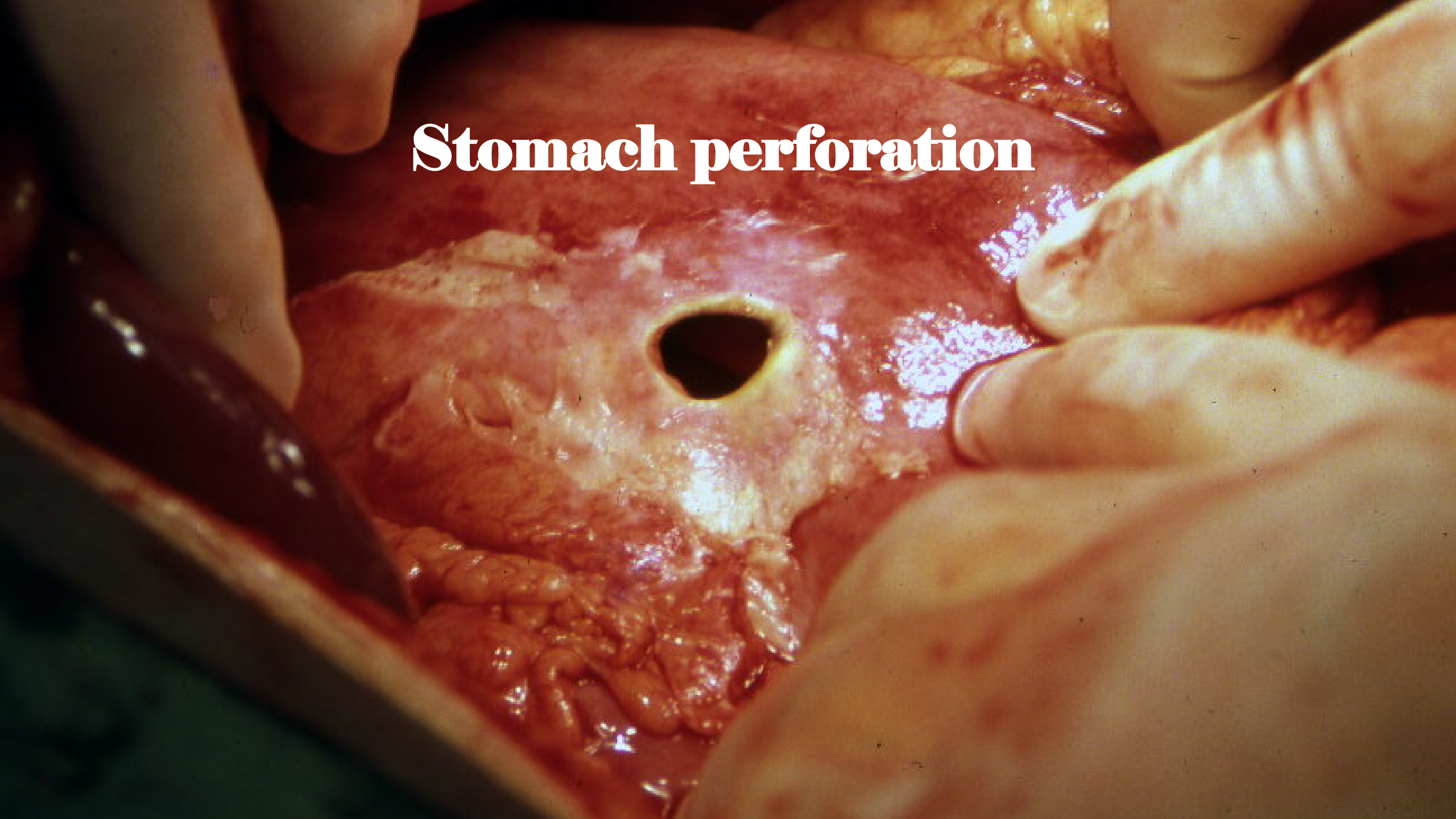
- First of all... TRUST**
- Success build more trust**



# Perforation



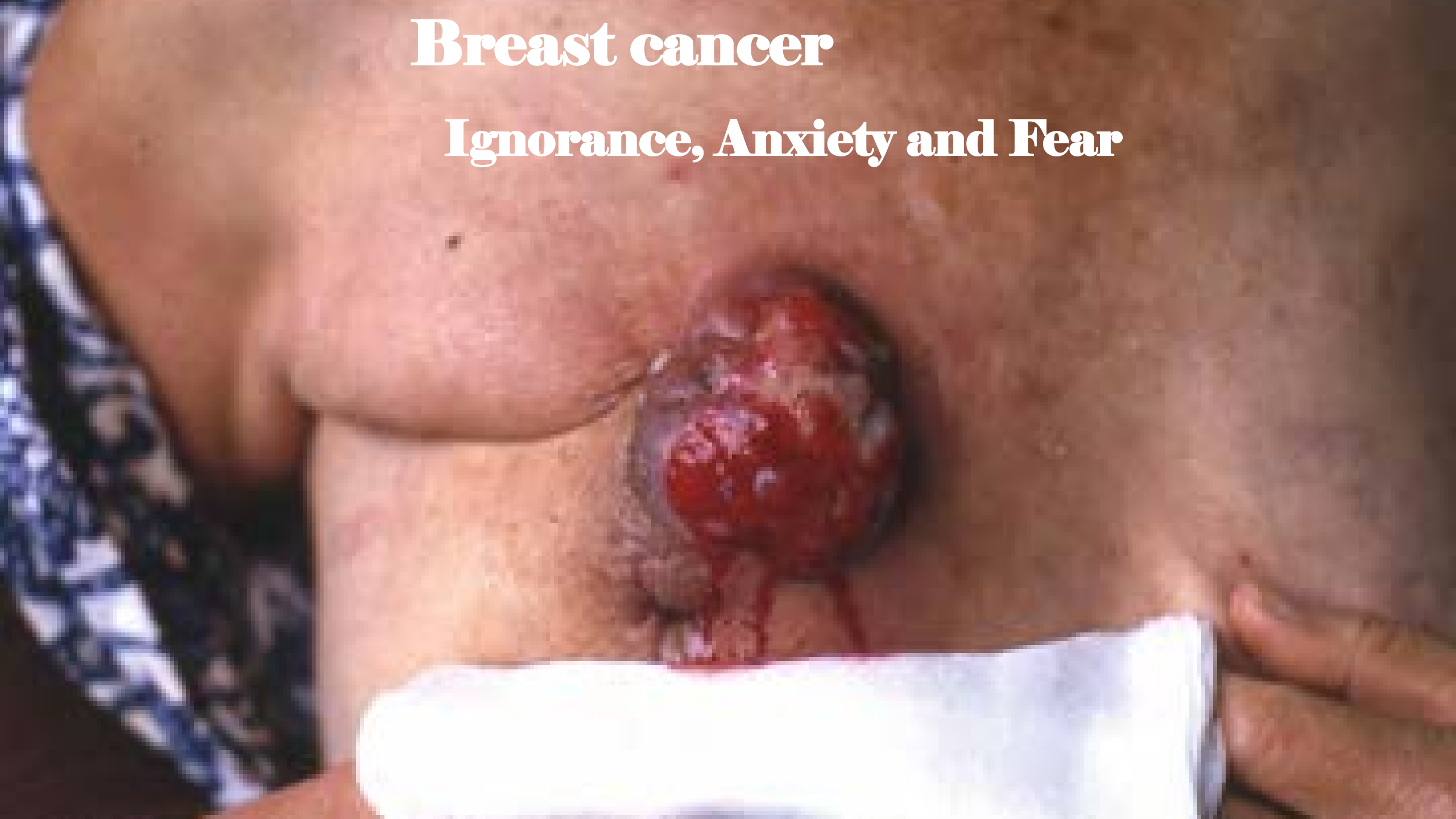# Stomach perforation



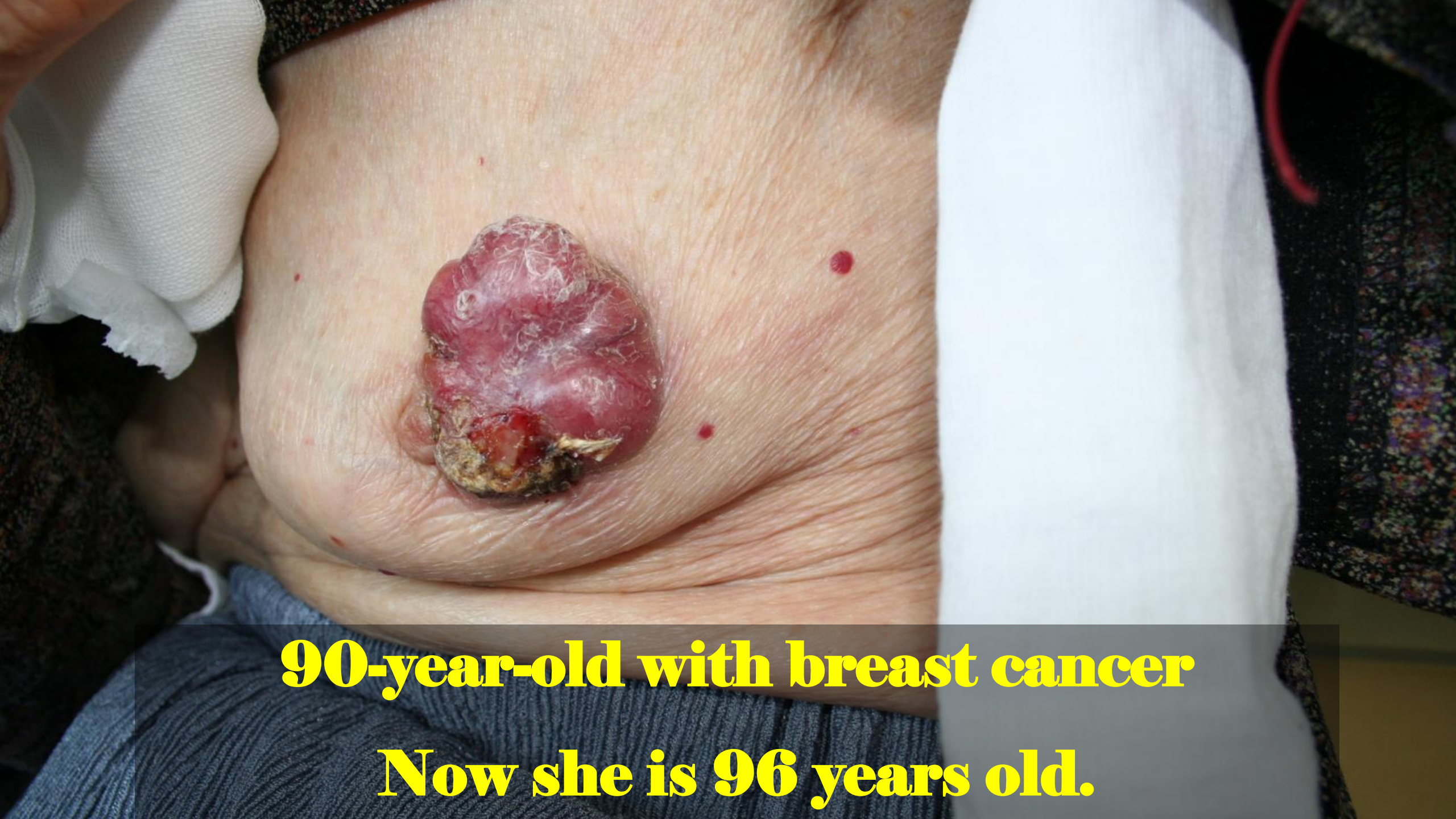

# Breast cancer

**Ignorance, Anxiety and Fear**







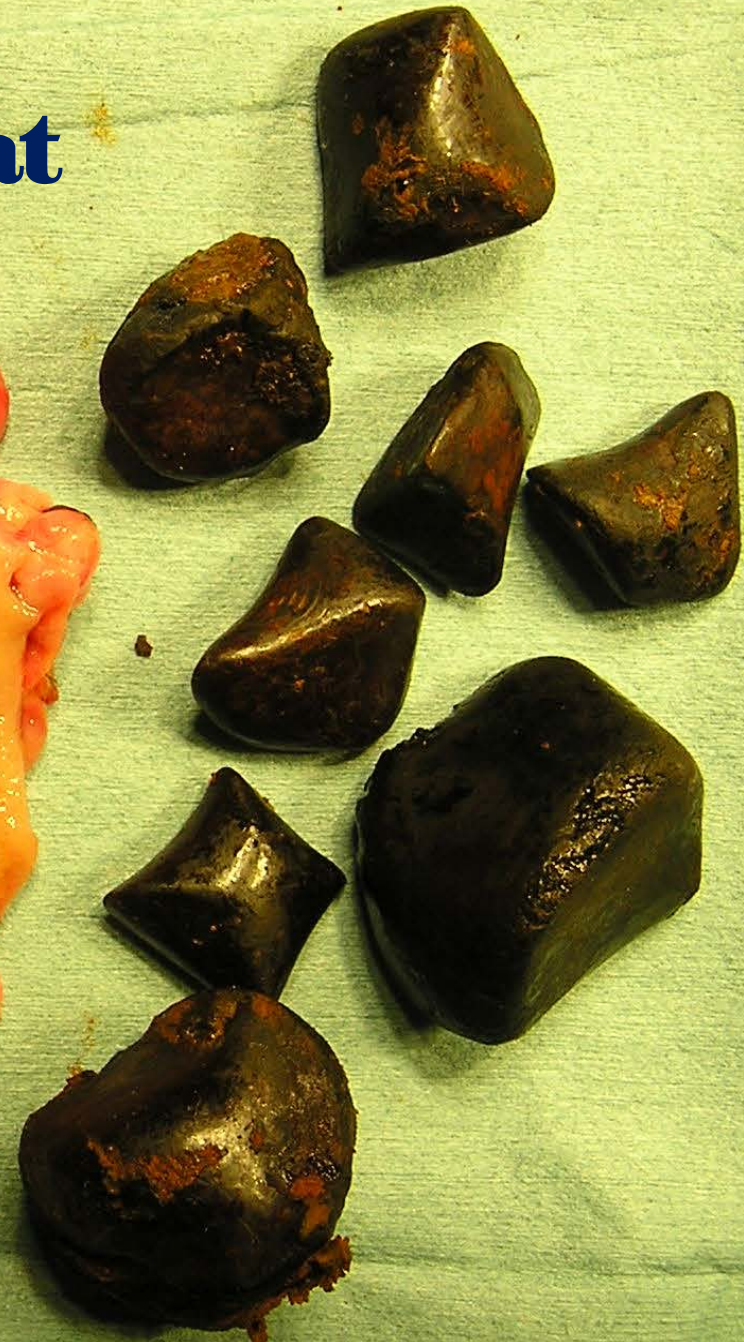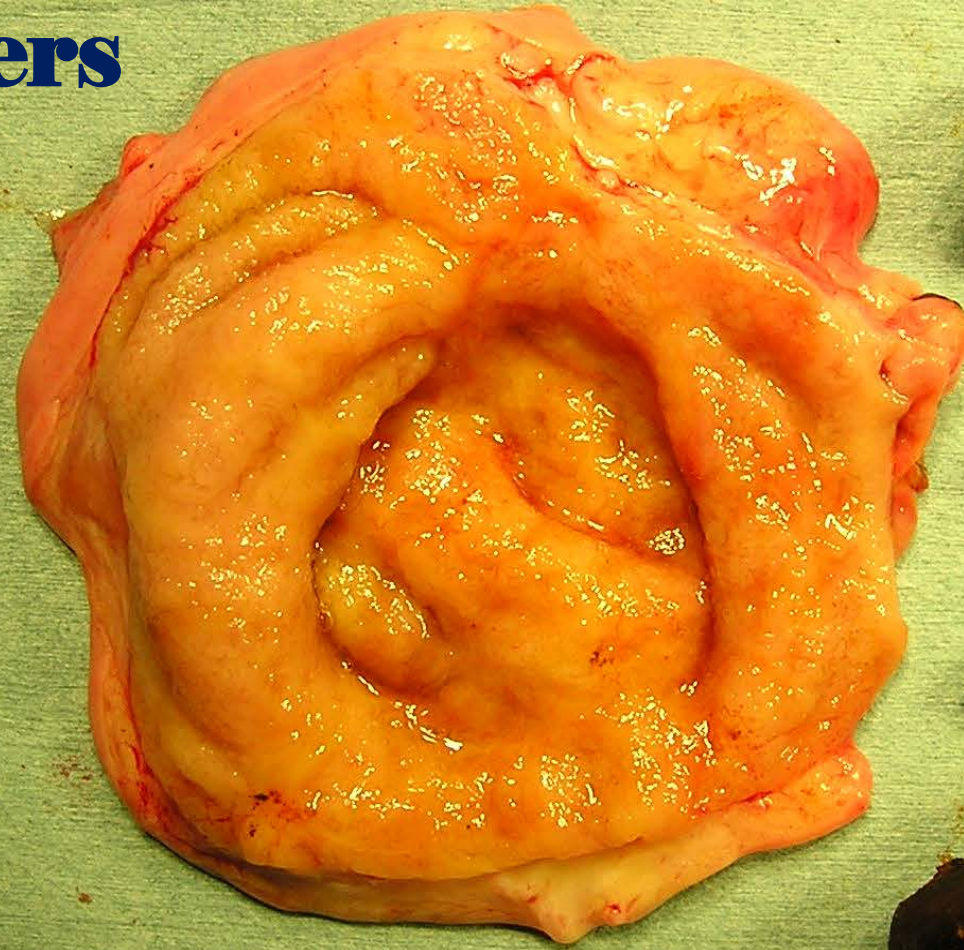**90-year-old with breast cancer**

**Now she is 96 years old.**



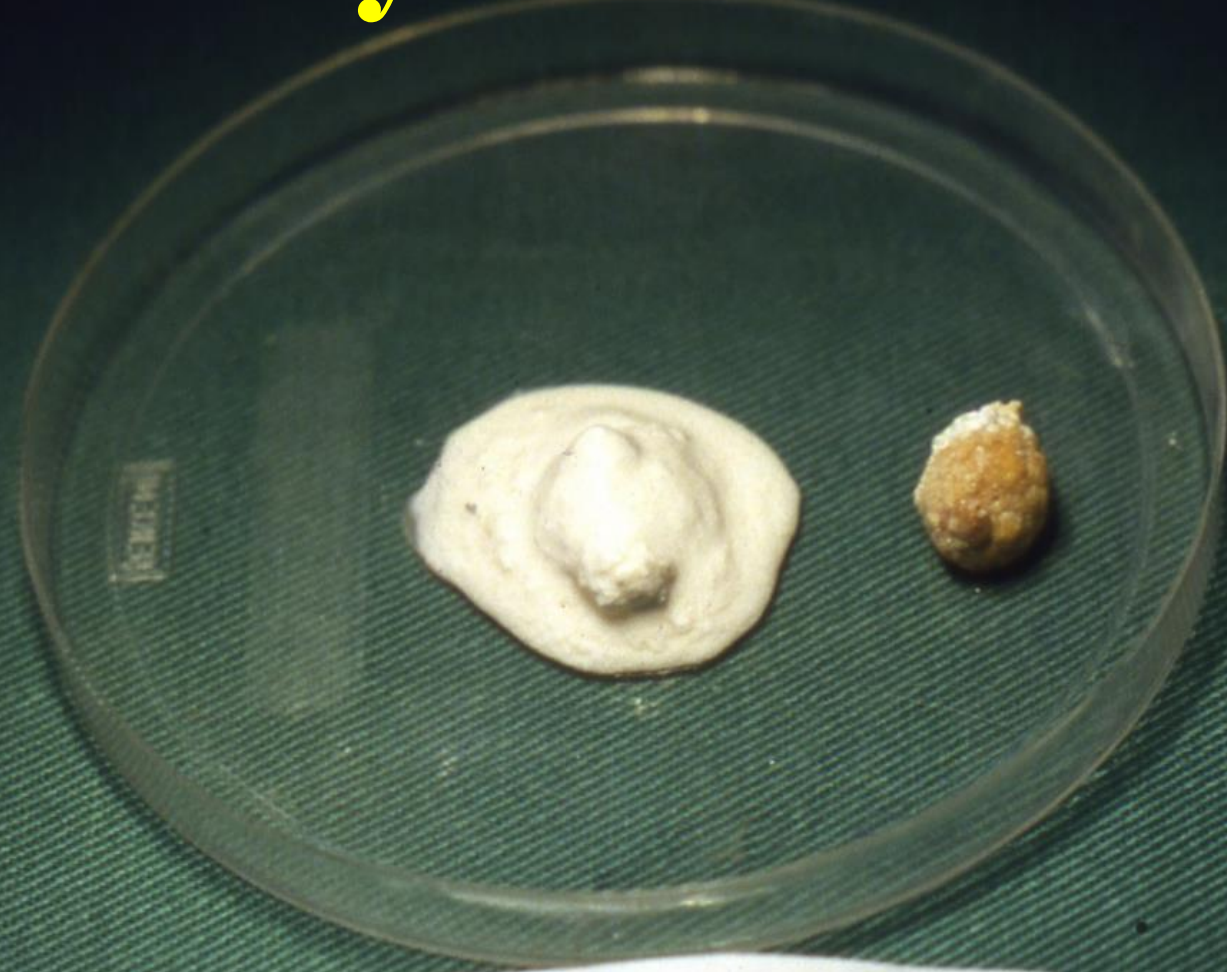**Trust needs no words**

**Only the result is all that matters**





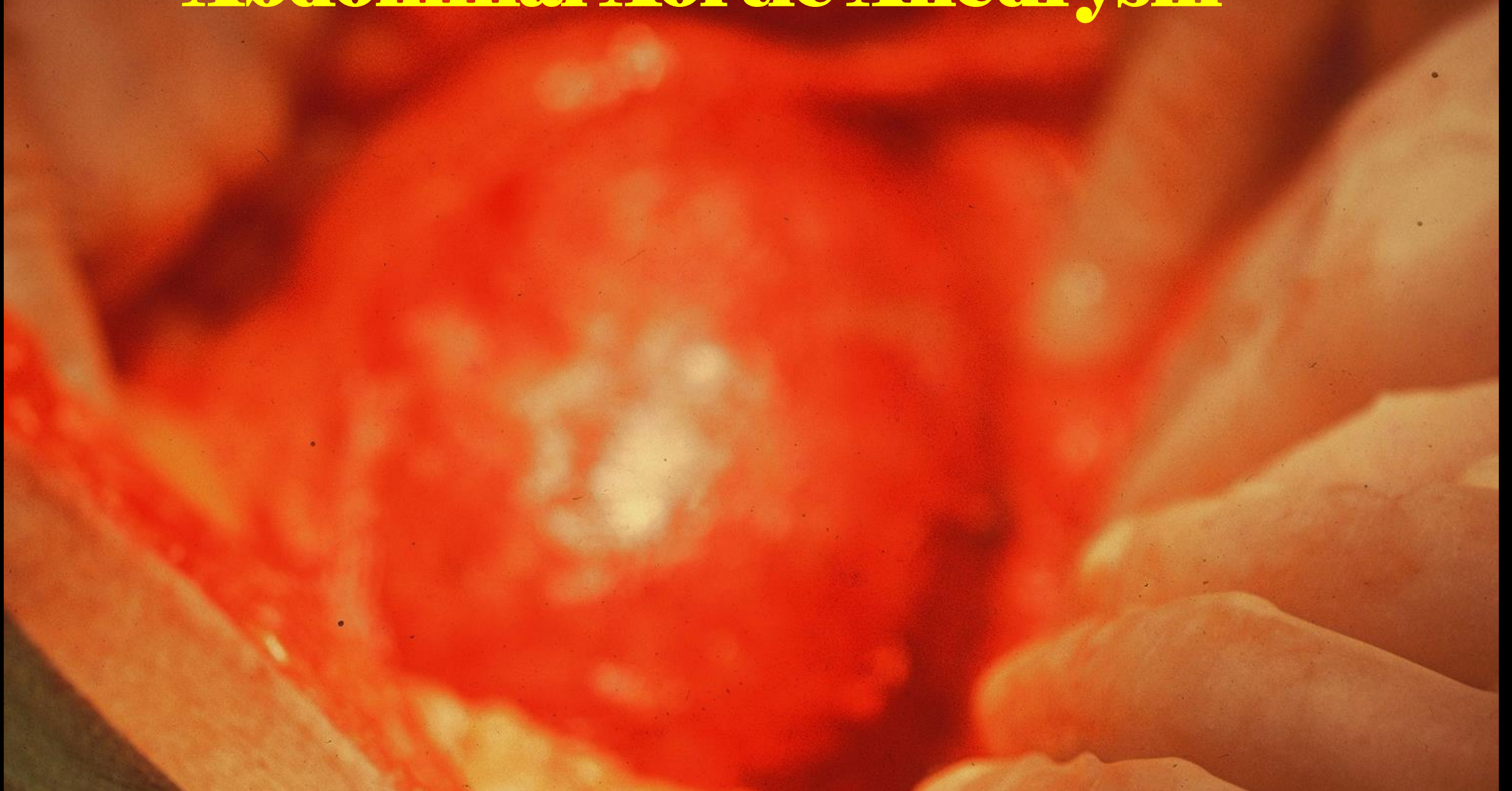# Limy bile and stone



廣野登茂子  
S57.3.10



# Abdominal Aortic Aneurysm




命は神様に

病気は先生に

**AAA**

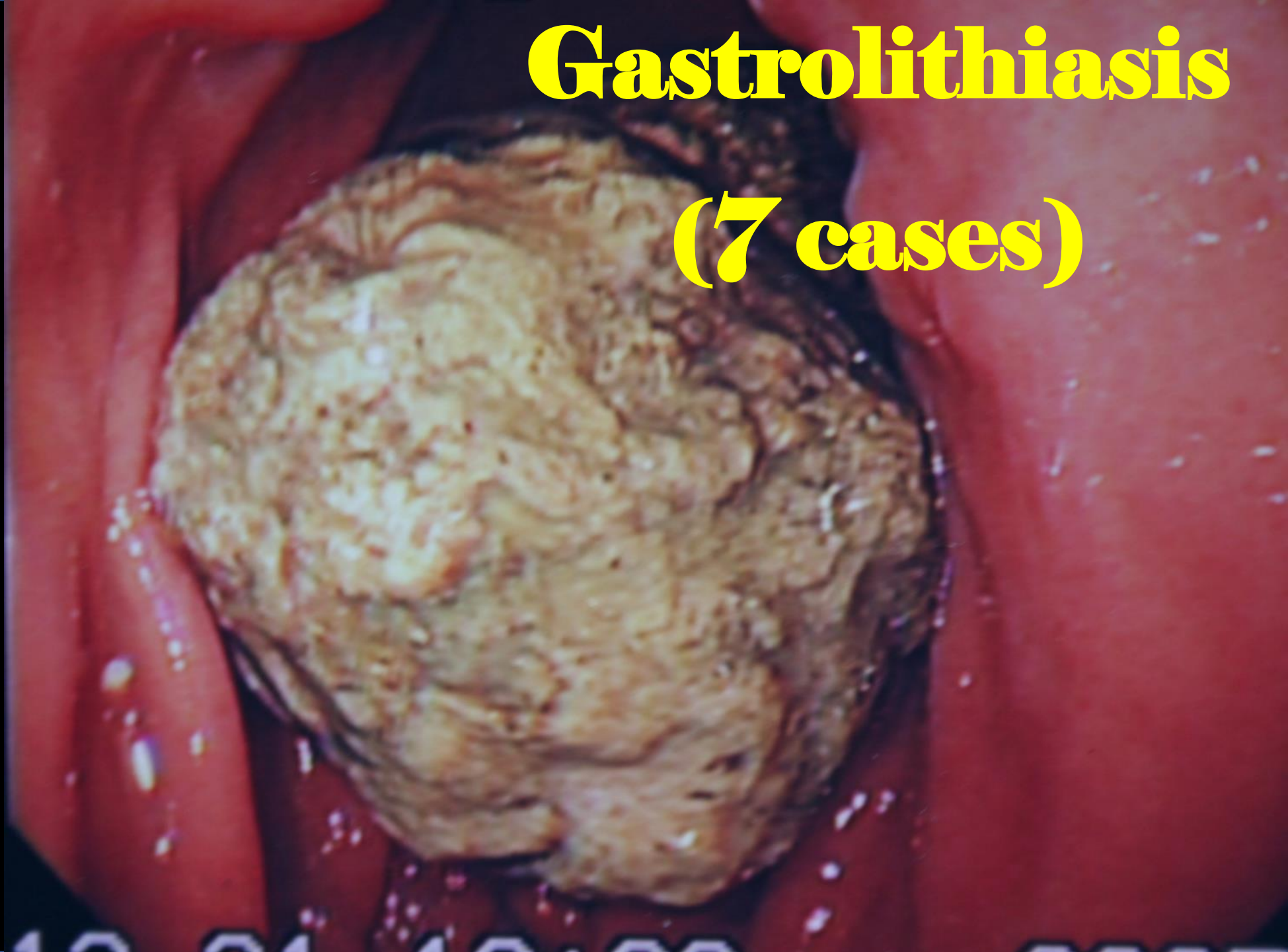
**He was alive**





# Gastrolithiasis

(7 cases)

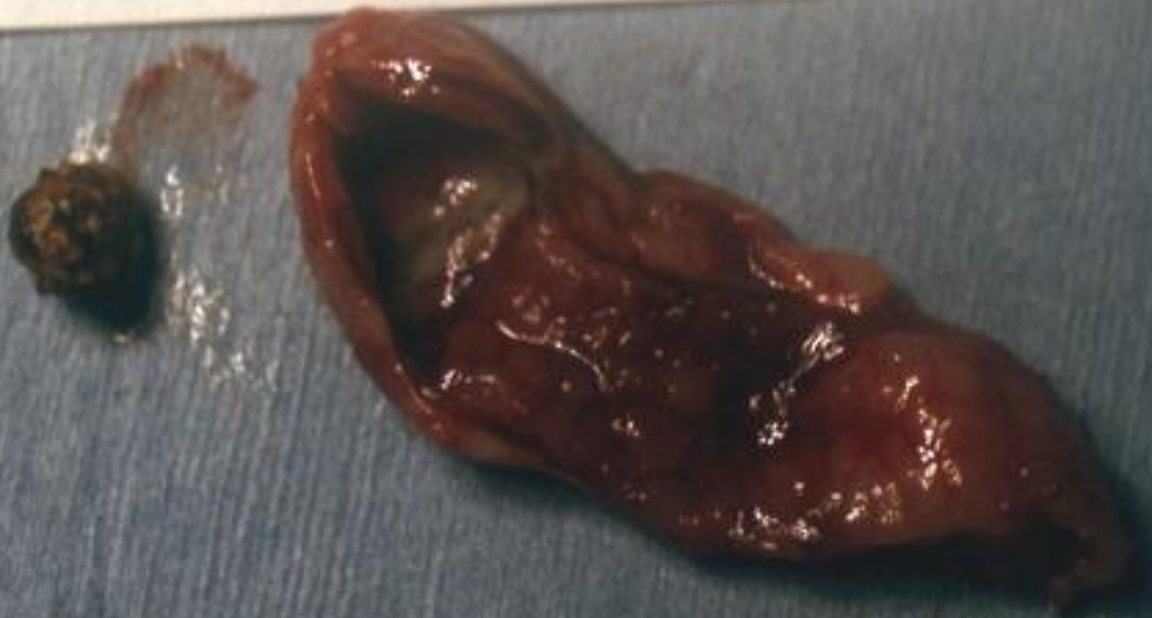



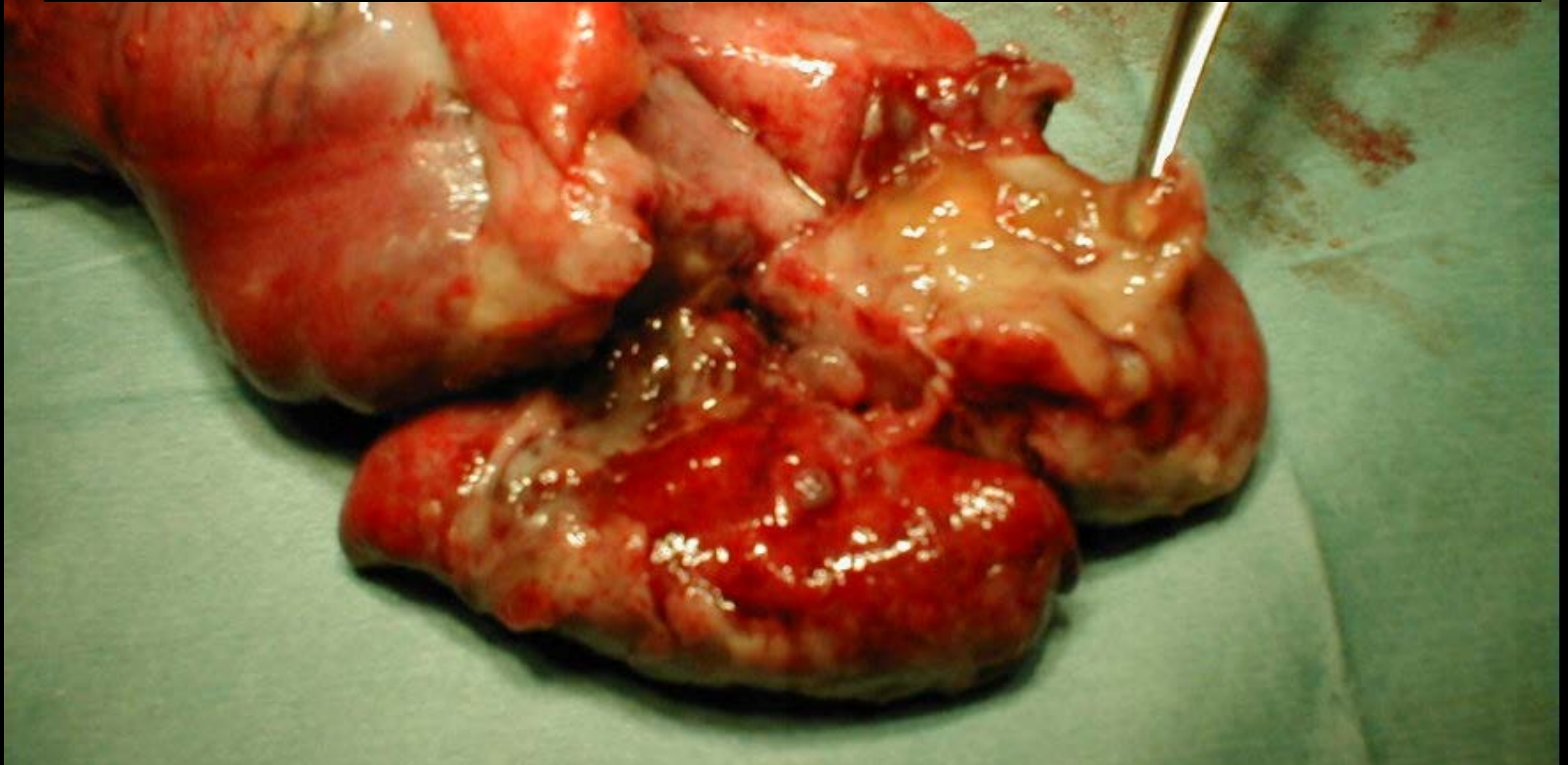
# Appendicitis (4-year-old)

46. 11. 17.

虫垂炎.

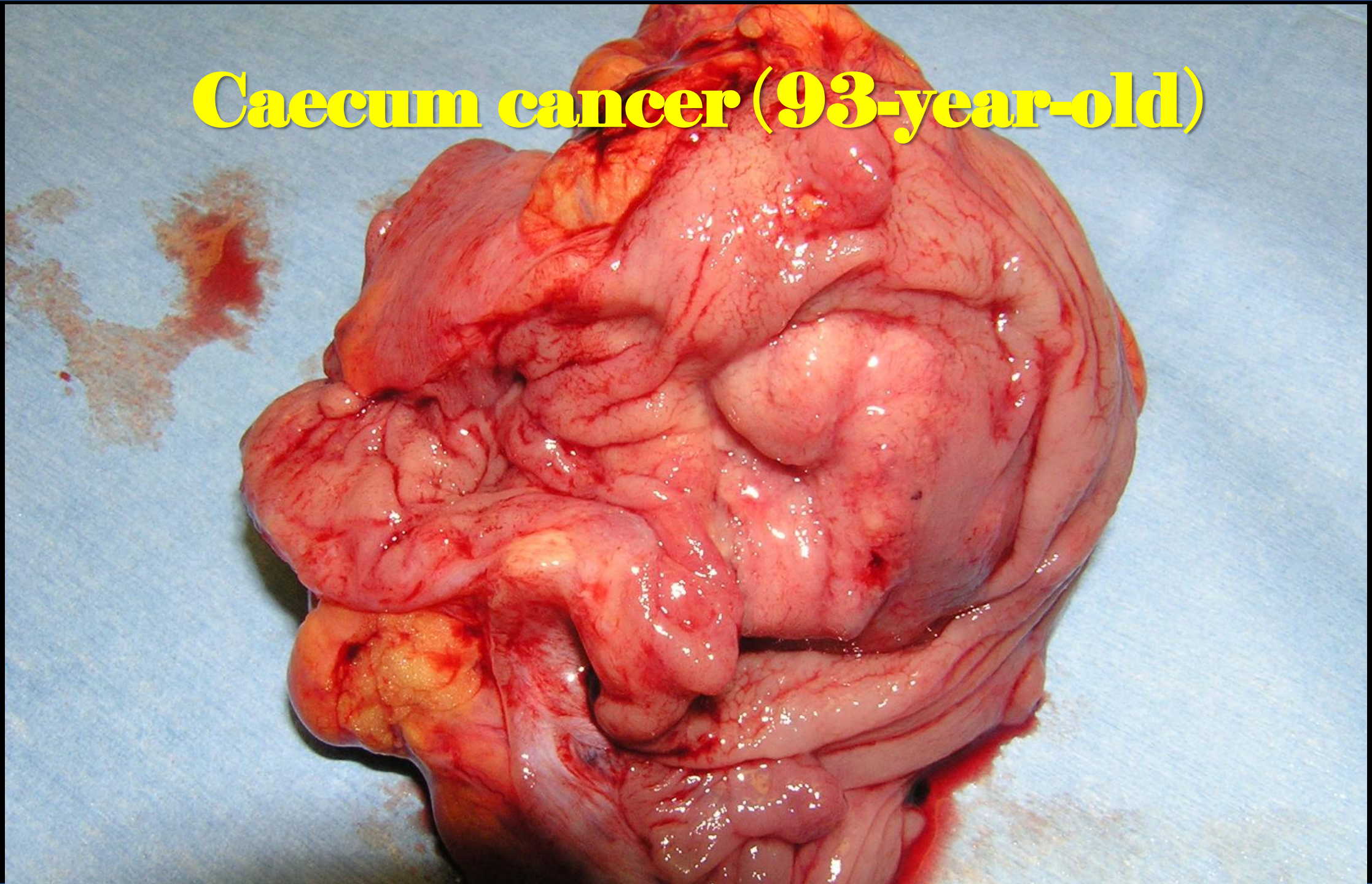


# Pseudomyxoma peritonei



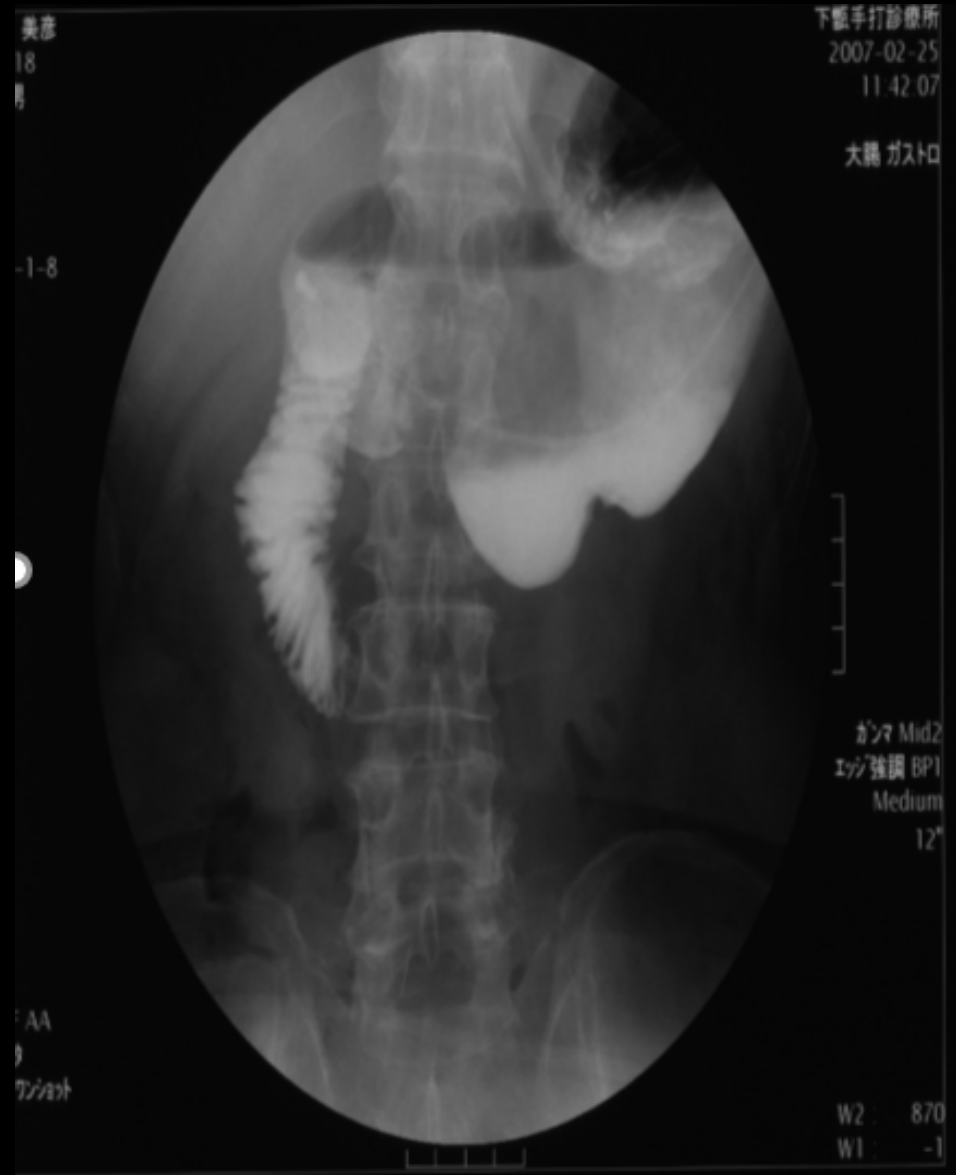

# Caecum cancer (93-year-old)

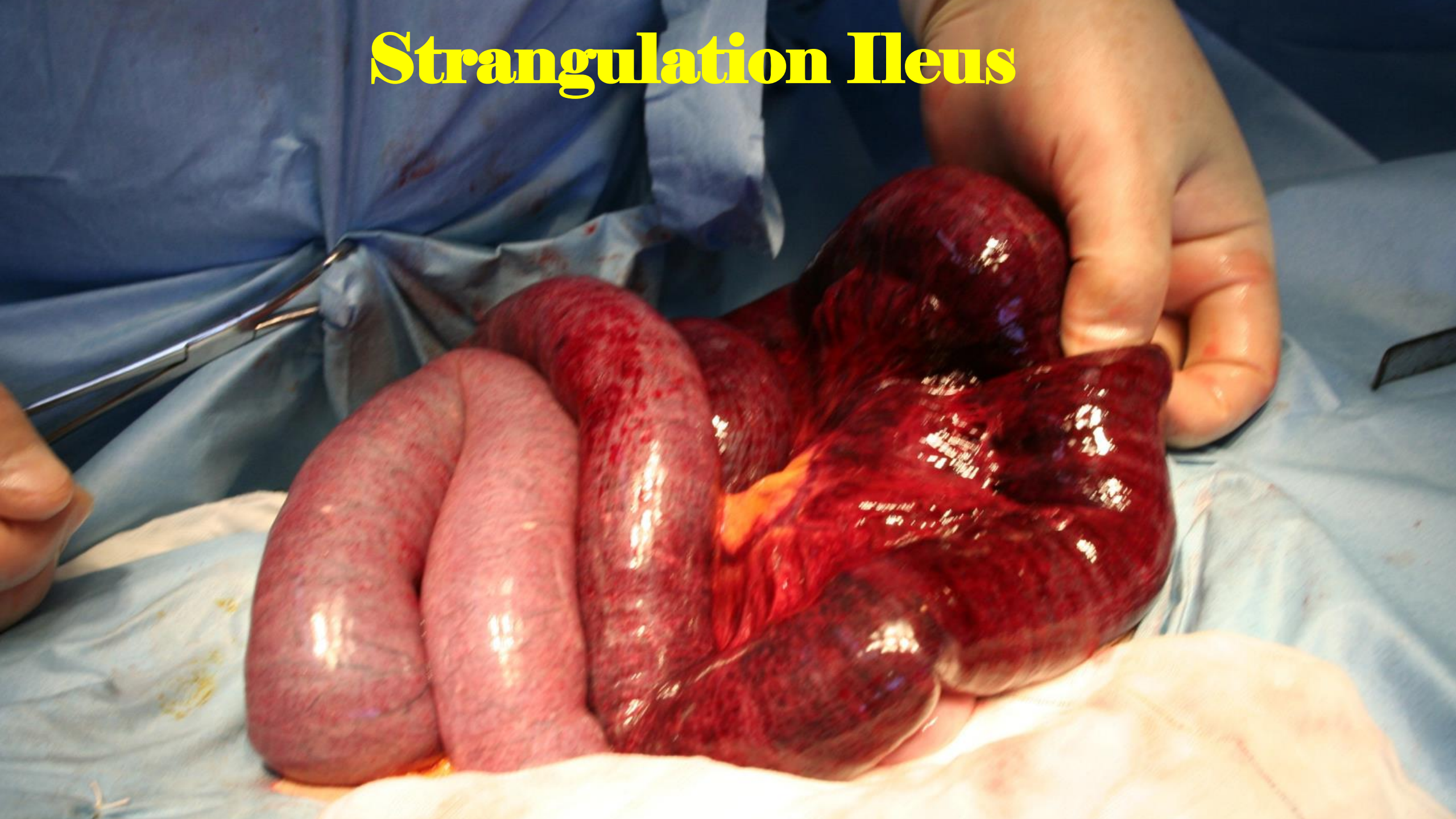



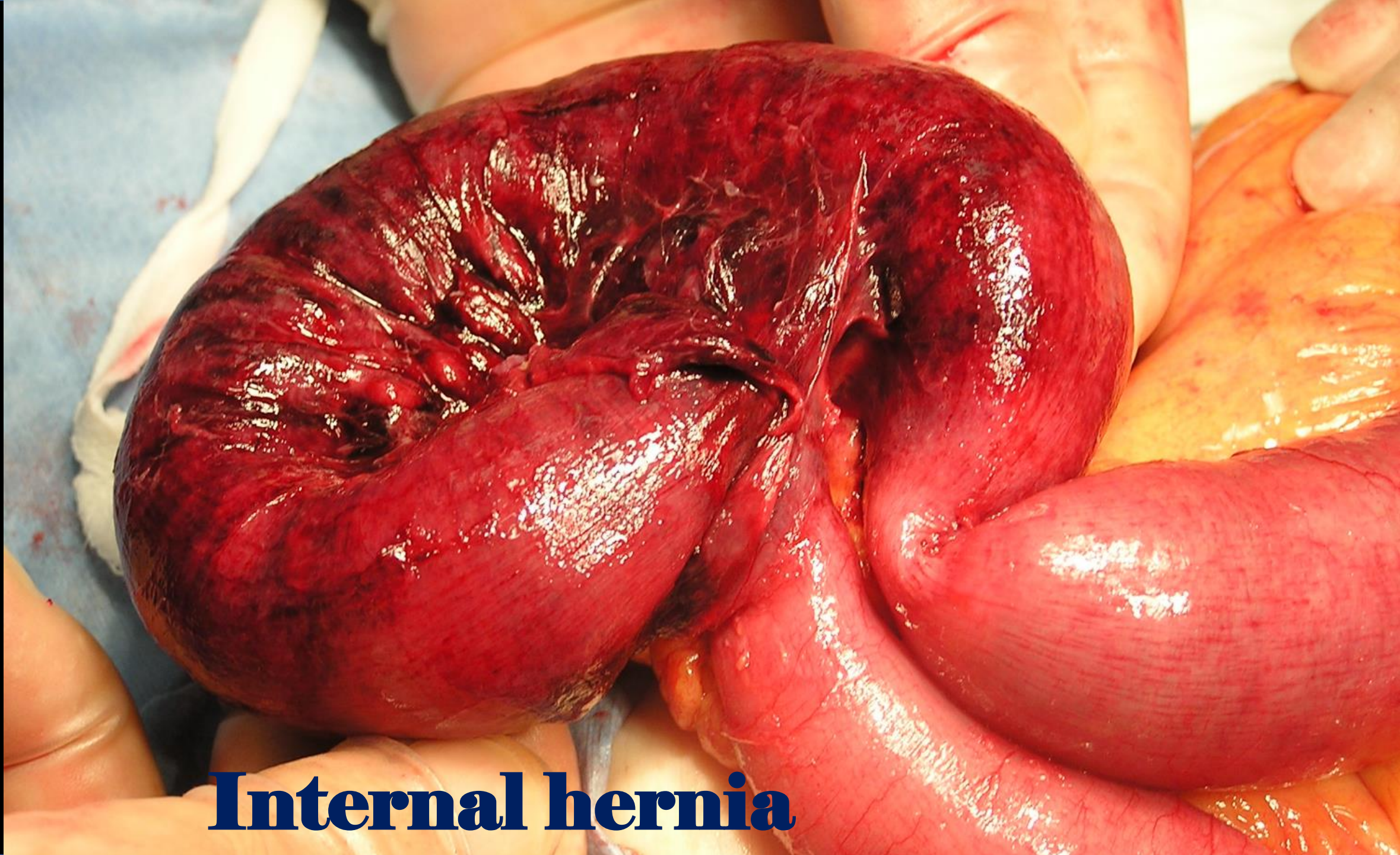
# Delayed onset ileus



# Strangulation Ileus



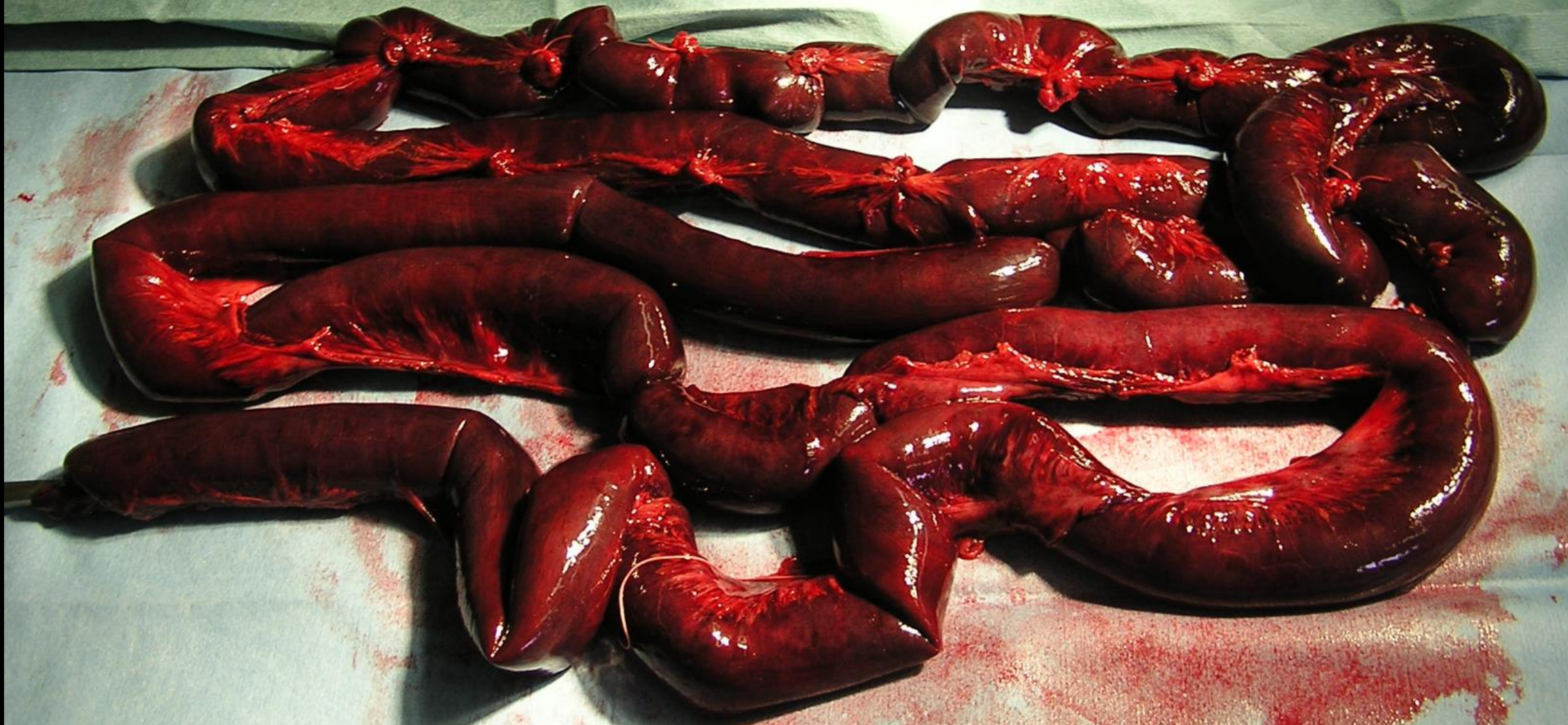



**Internal hernia**

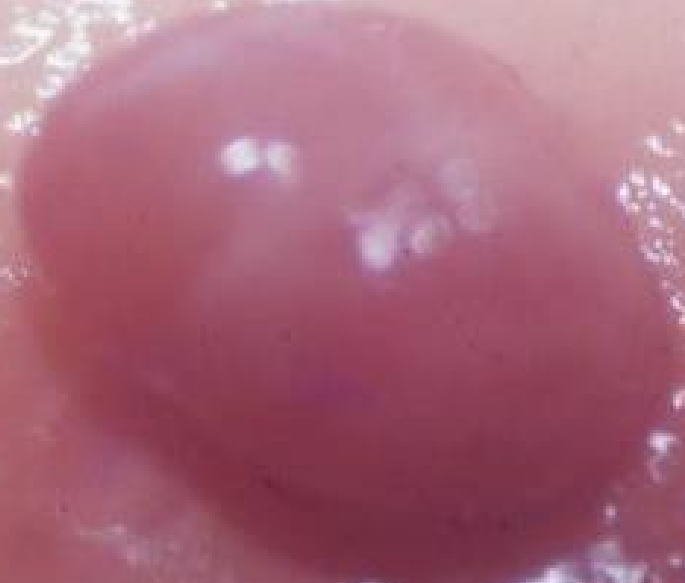

# Internal hernia (unable to save the patient)





# **Schwannoma of the stomach**

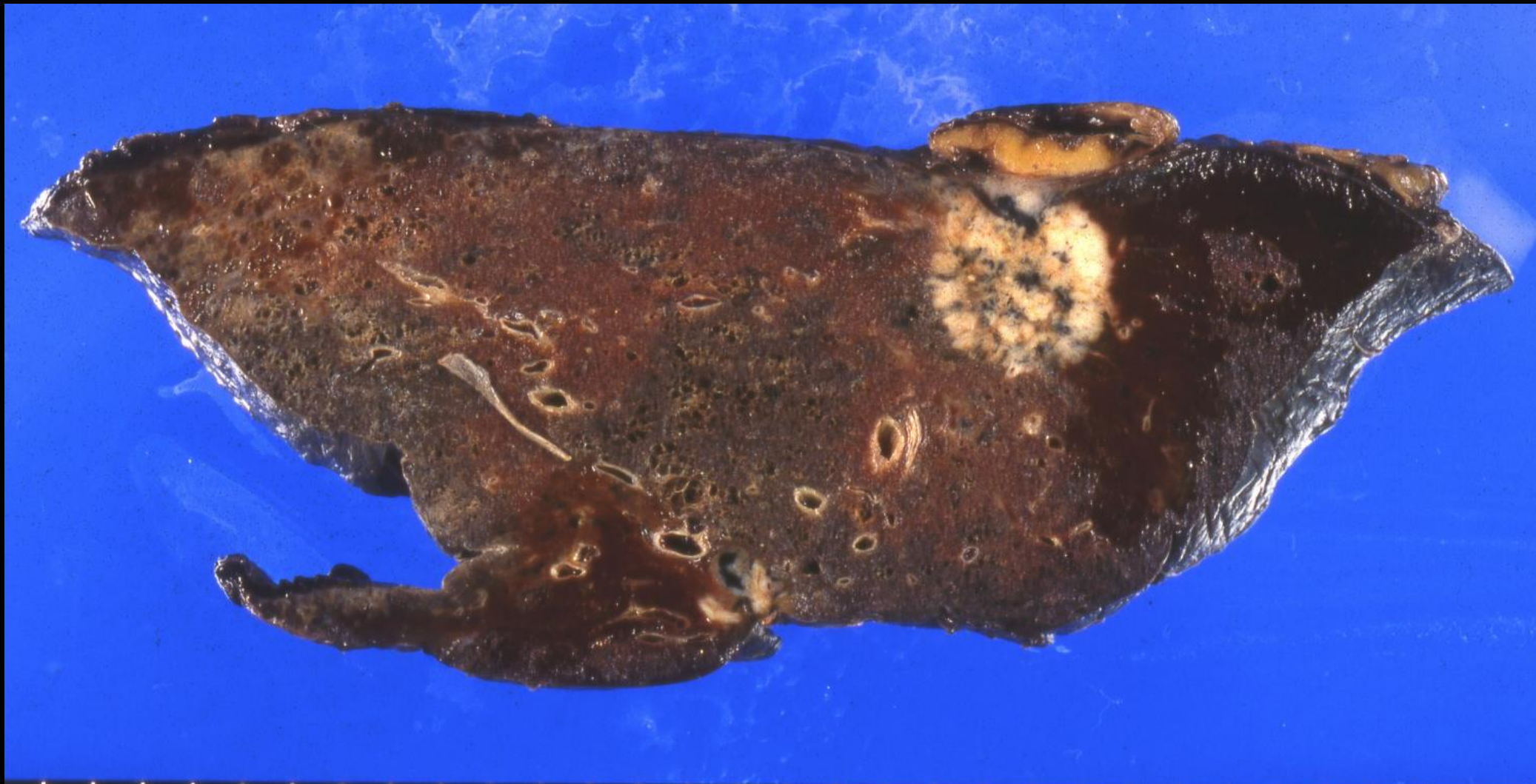



**Scope of Practice**

**Oncology**

# Lung cancer



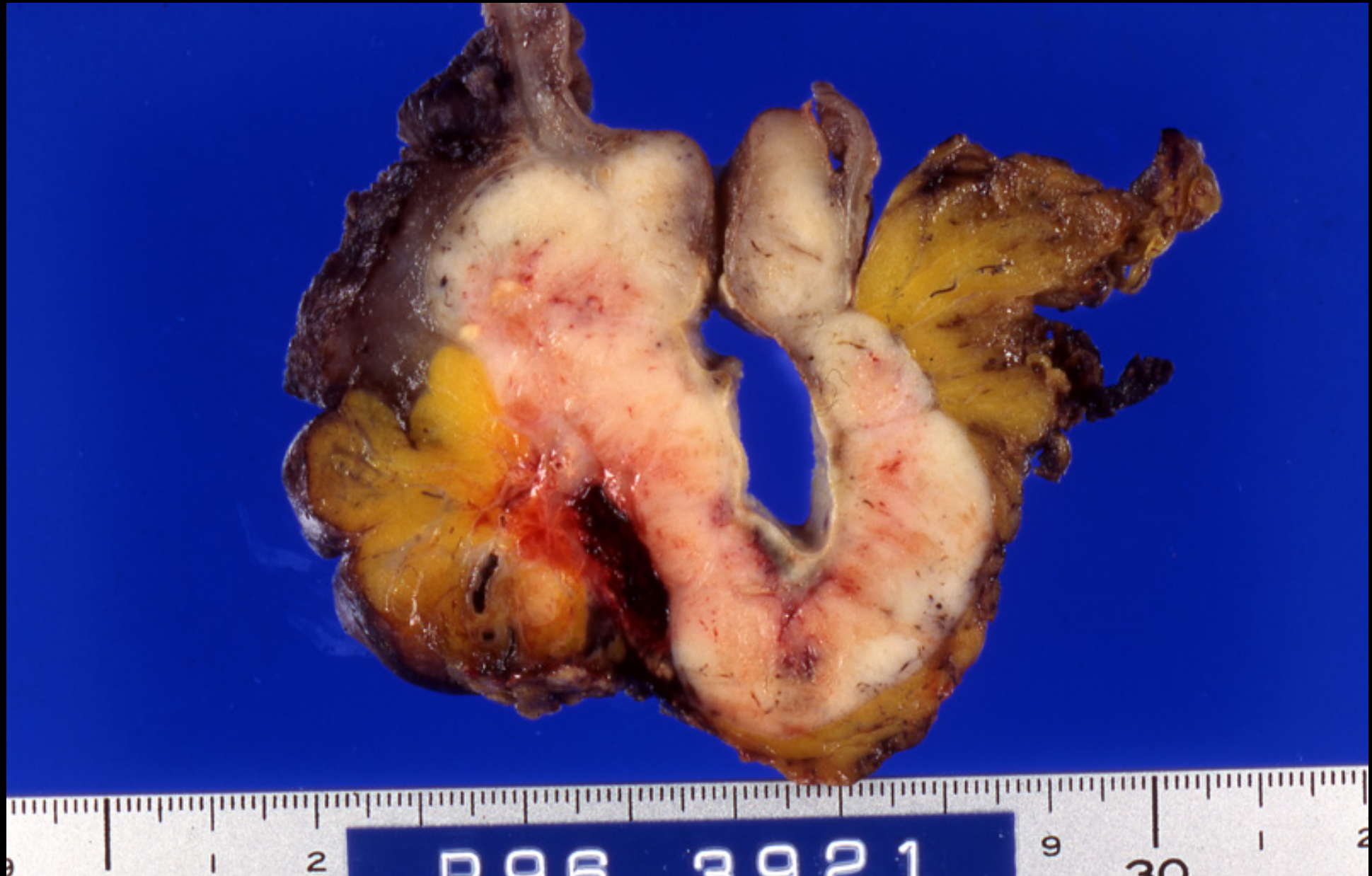20

P. 87. 11079

30

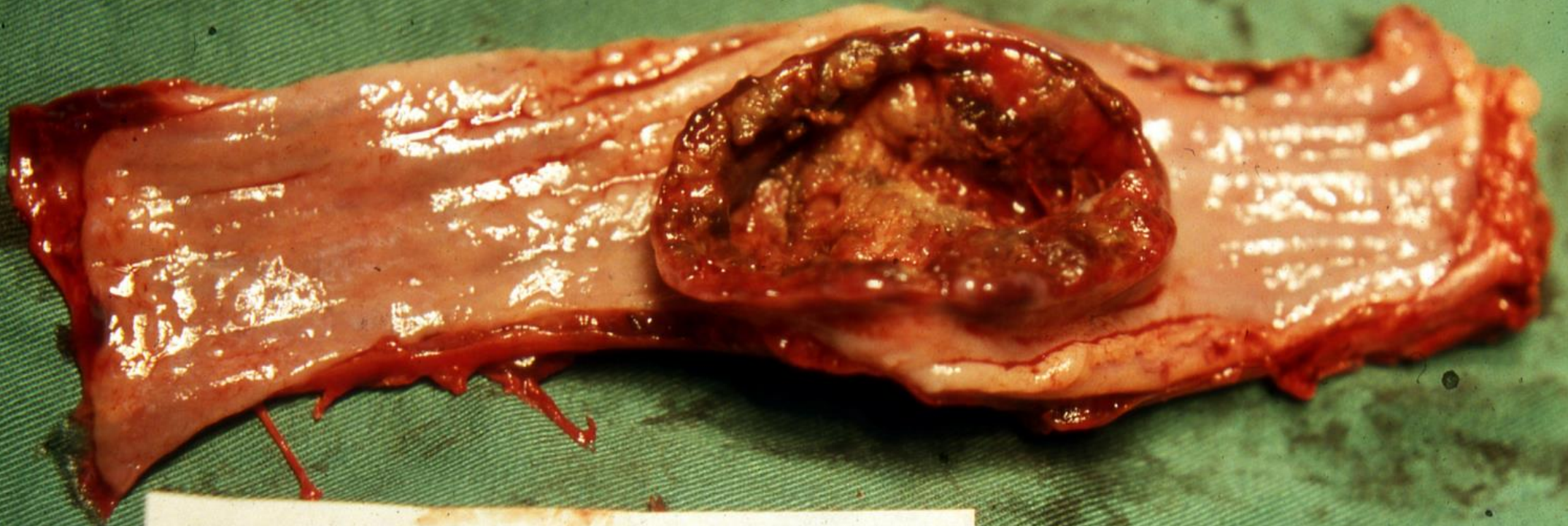


# Leiomyosarcoma (jejunum)





# Esophageal cancer

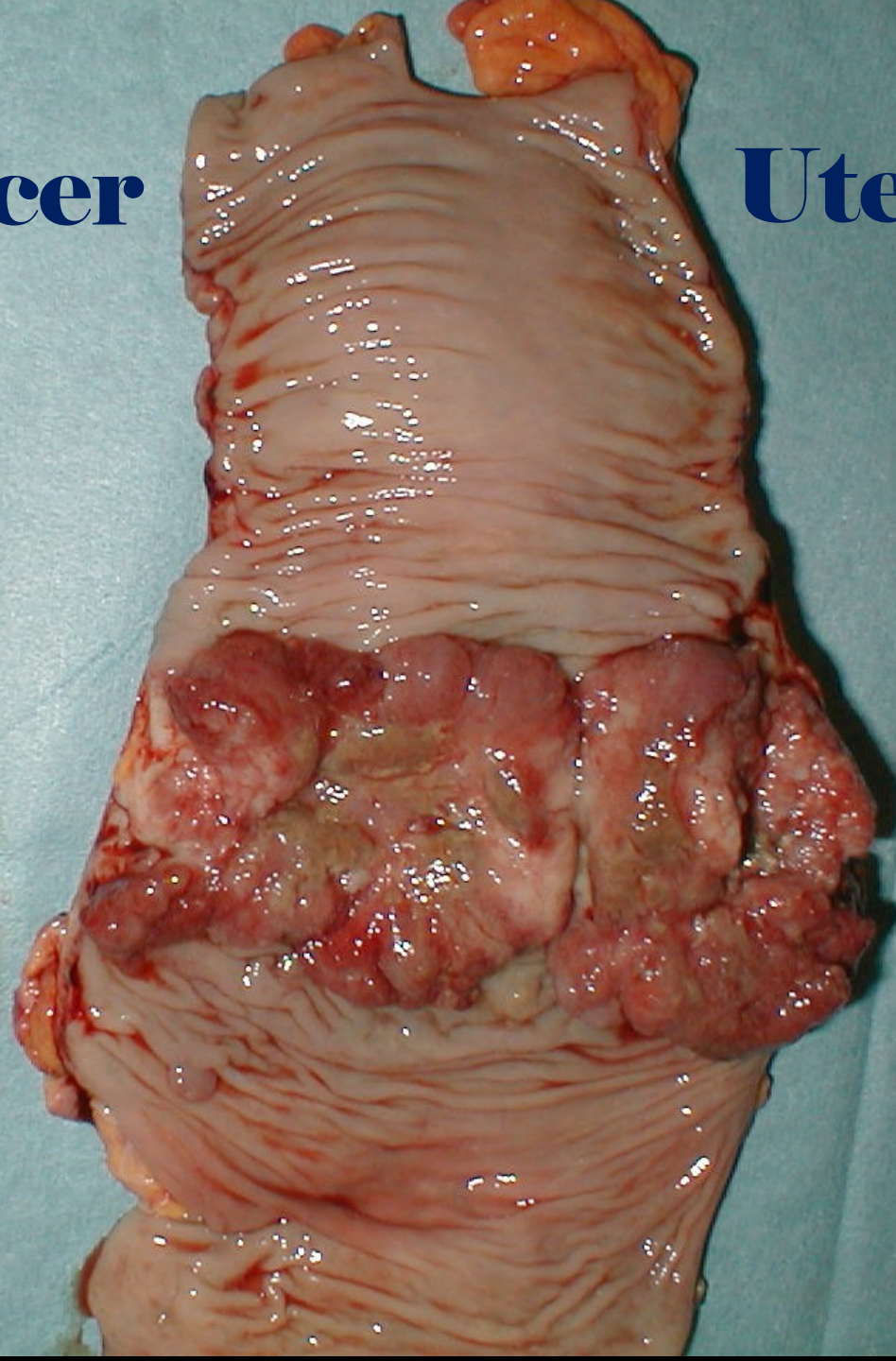
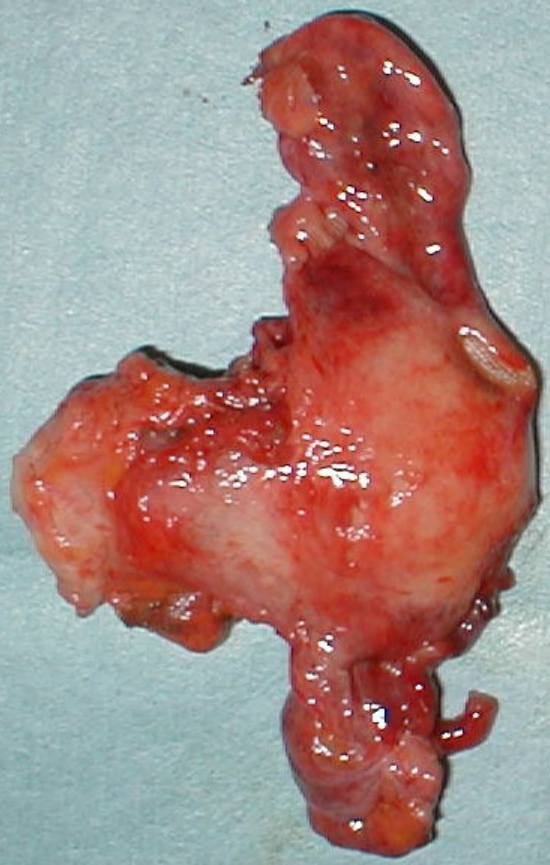


食道癌 HH 74才  
563. 3. 28. 打



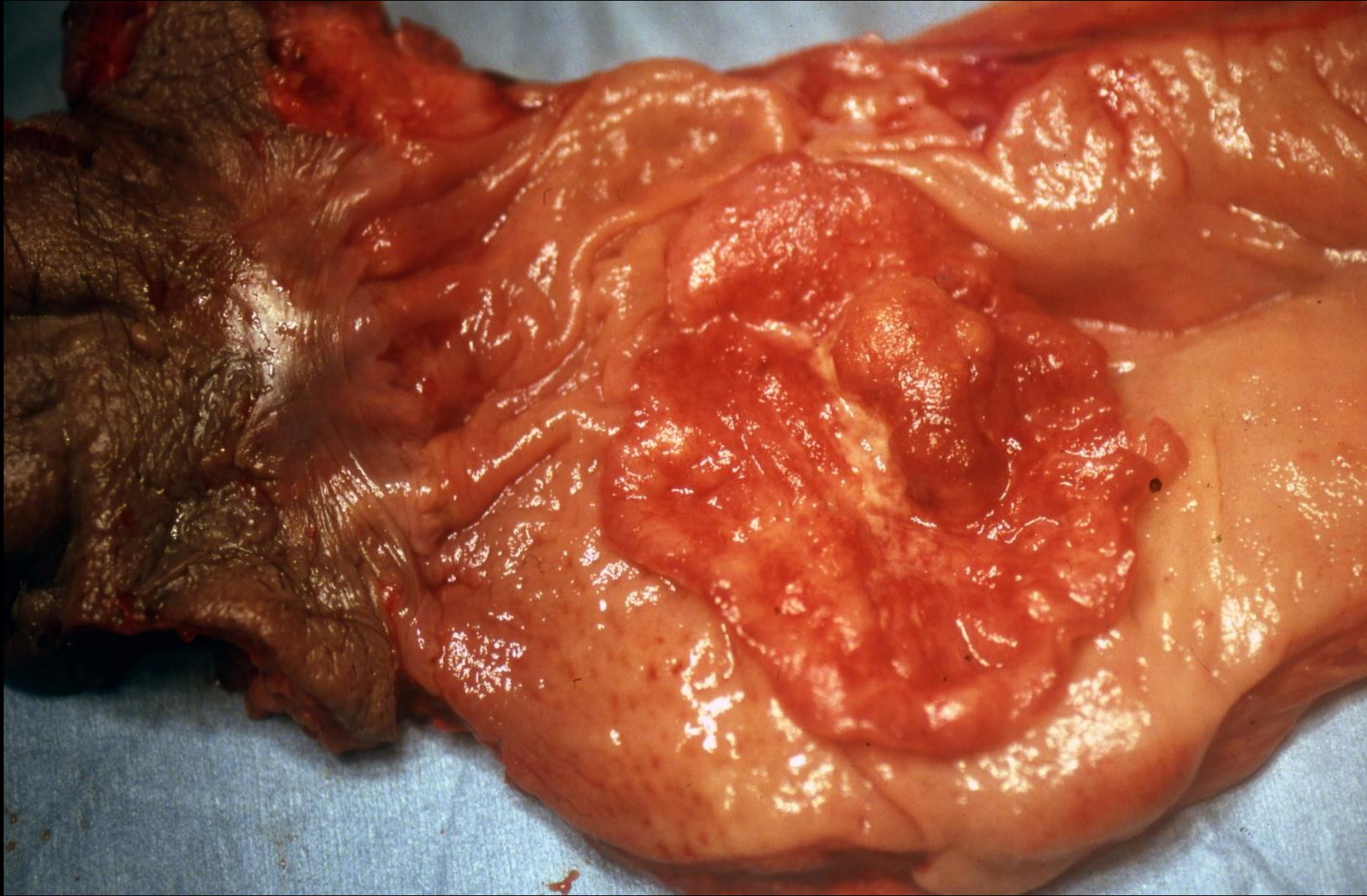
**Rectal cancer**

**Uterus**





# Haemorrhoid & Rectal cancer

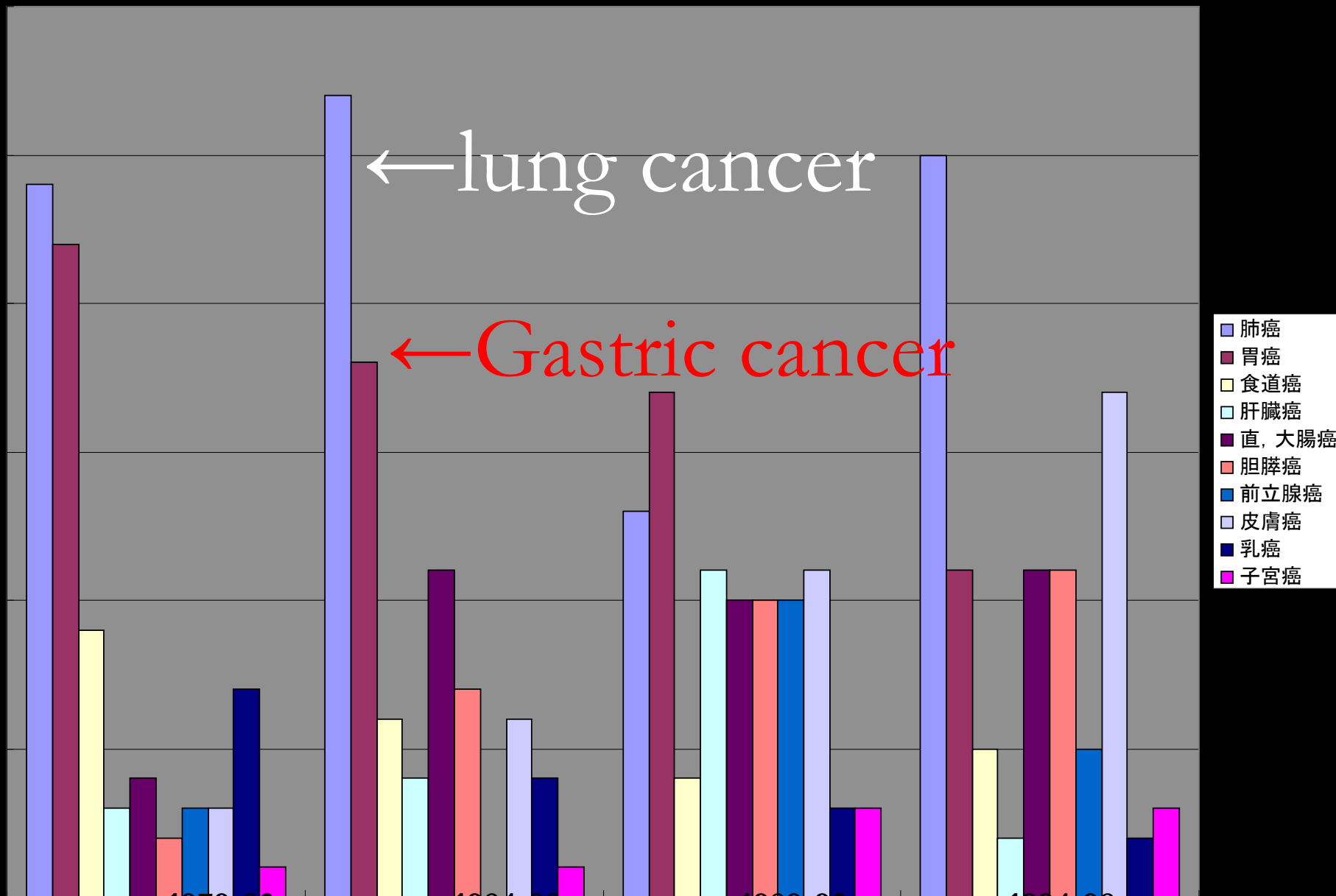






**Skin cancer is increasing on the island**

# Cancer 439 cases (1979~1998)

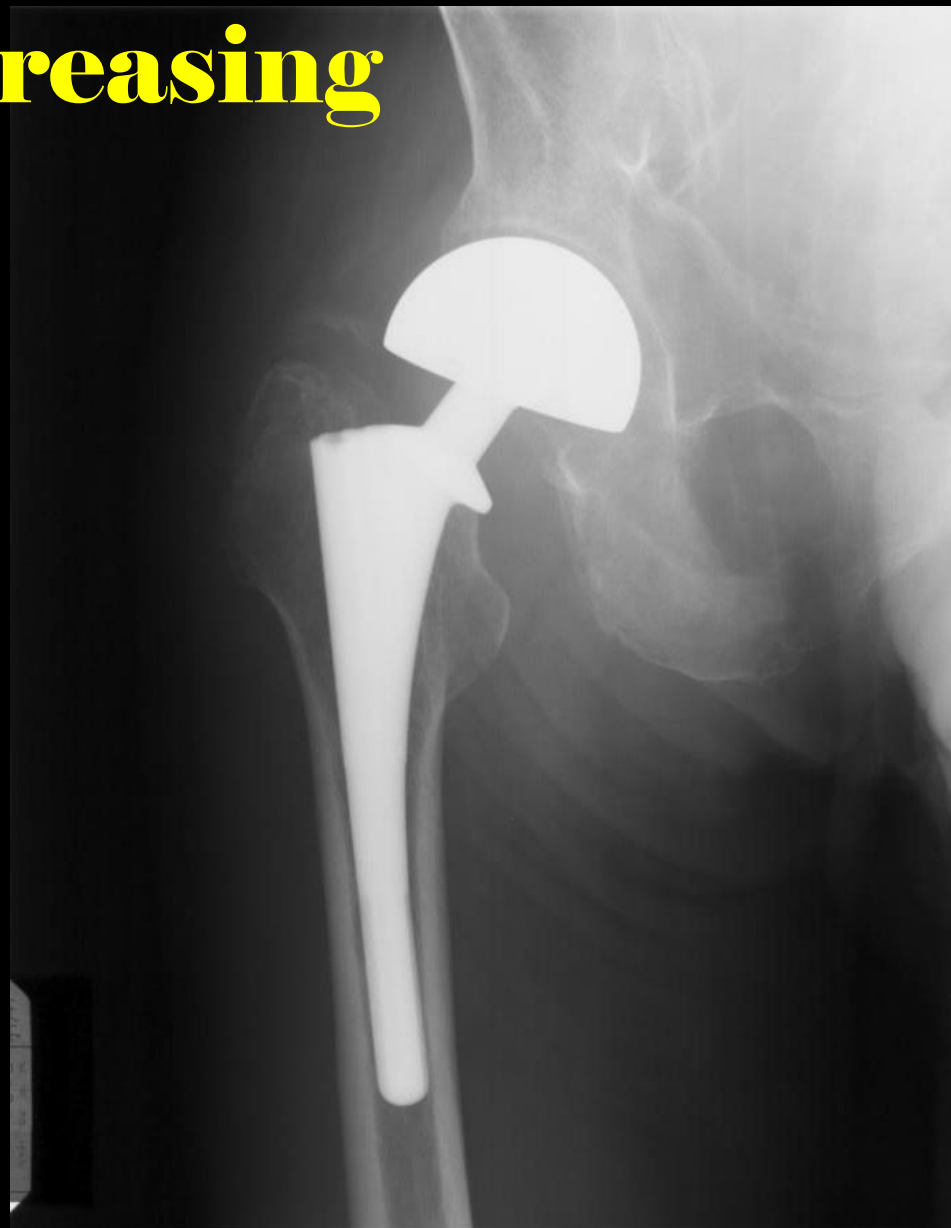




**Scope of Practice**

**Orthopedics**

**Challenging,  
fracture is increasing**

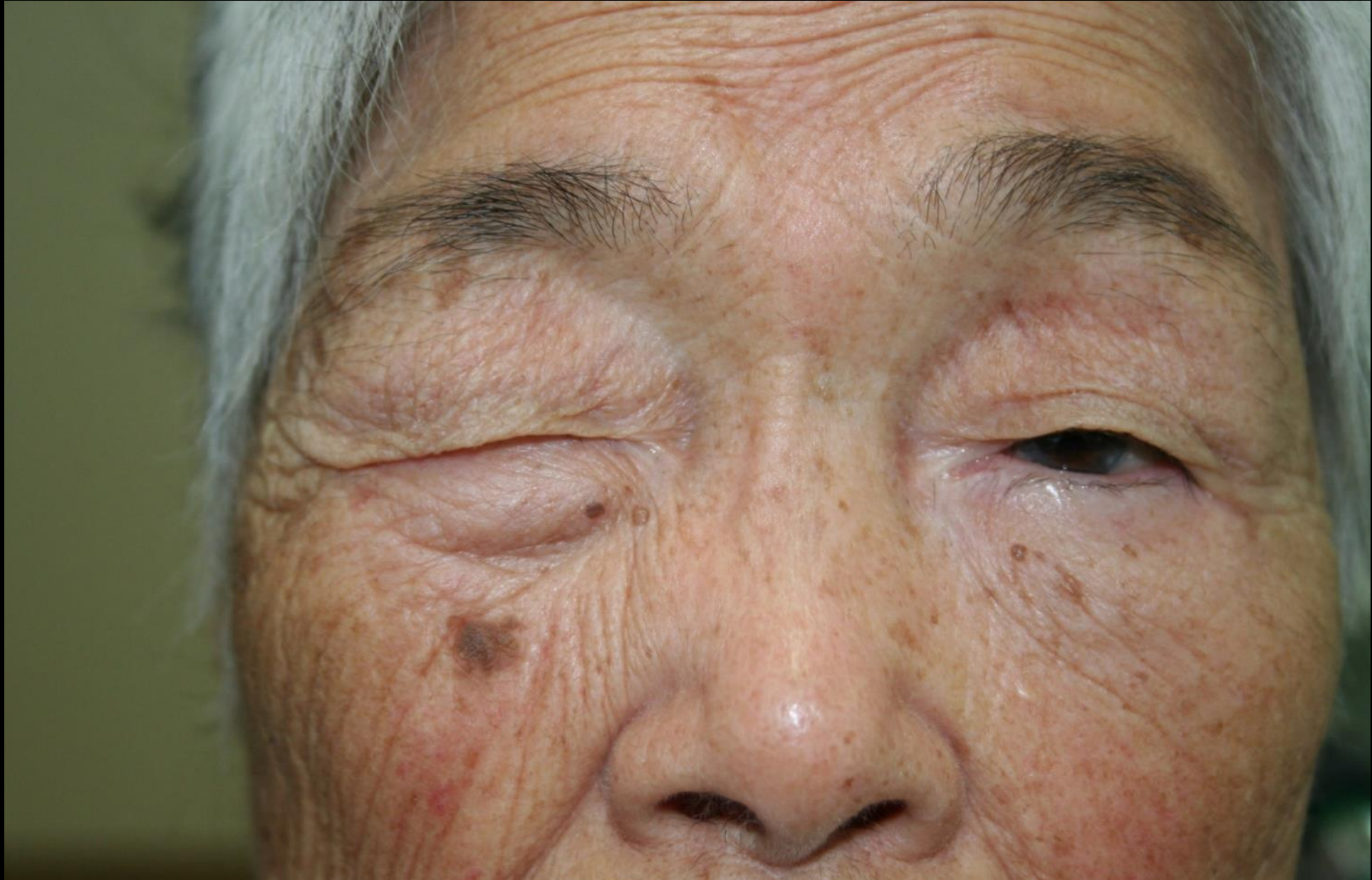



**Scope of Practice**

**Cosmetic surgery**

**C.C. Please do something for my eye!**





**I can see now!**



**Scope of Practice**

**Retrieval Medicine**



An elderly woman with short, grey hair is sitting on a hospital bed. She is wearing a white hospital gown with a blue floral pattern. She is smiling slightly and looking towards the camera. The background shows a hospital room with green curtains, a calendar on the wall, and another hospital bed in the distance.

**Peritonitis during a typhoon is awful.  
If helicopter is not available, we have to do it.**



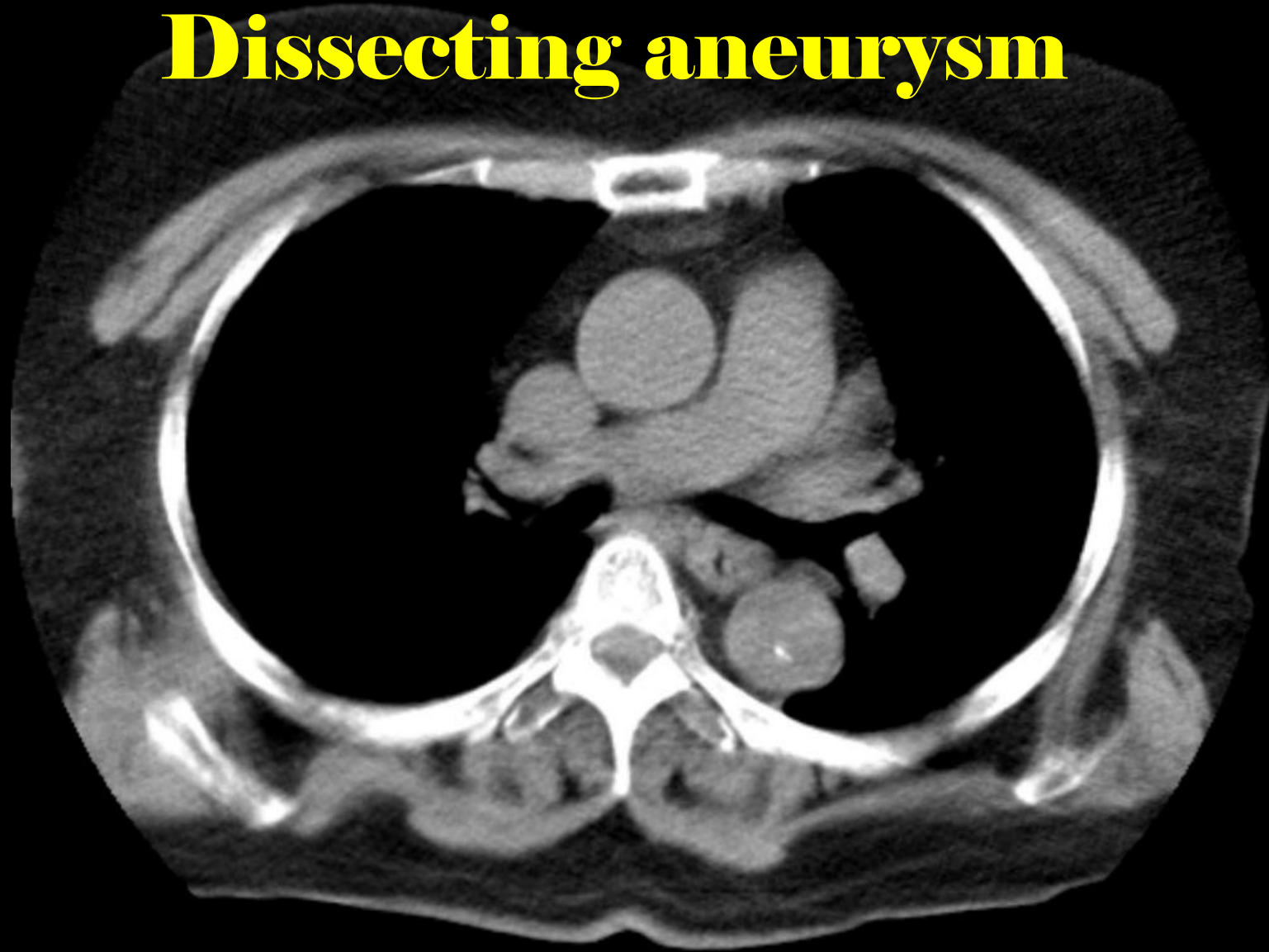
# Retrieval to mainland are increasing





**Telemedicine -remote image reading**

**Dissecting aneurysm**





# Medical Education

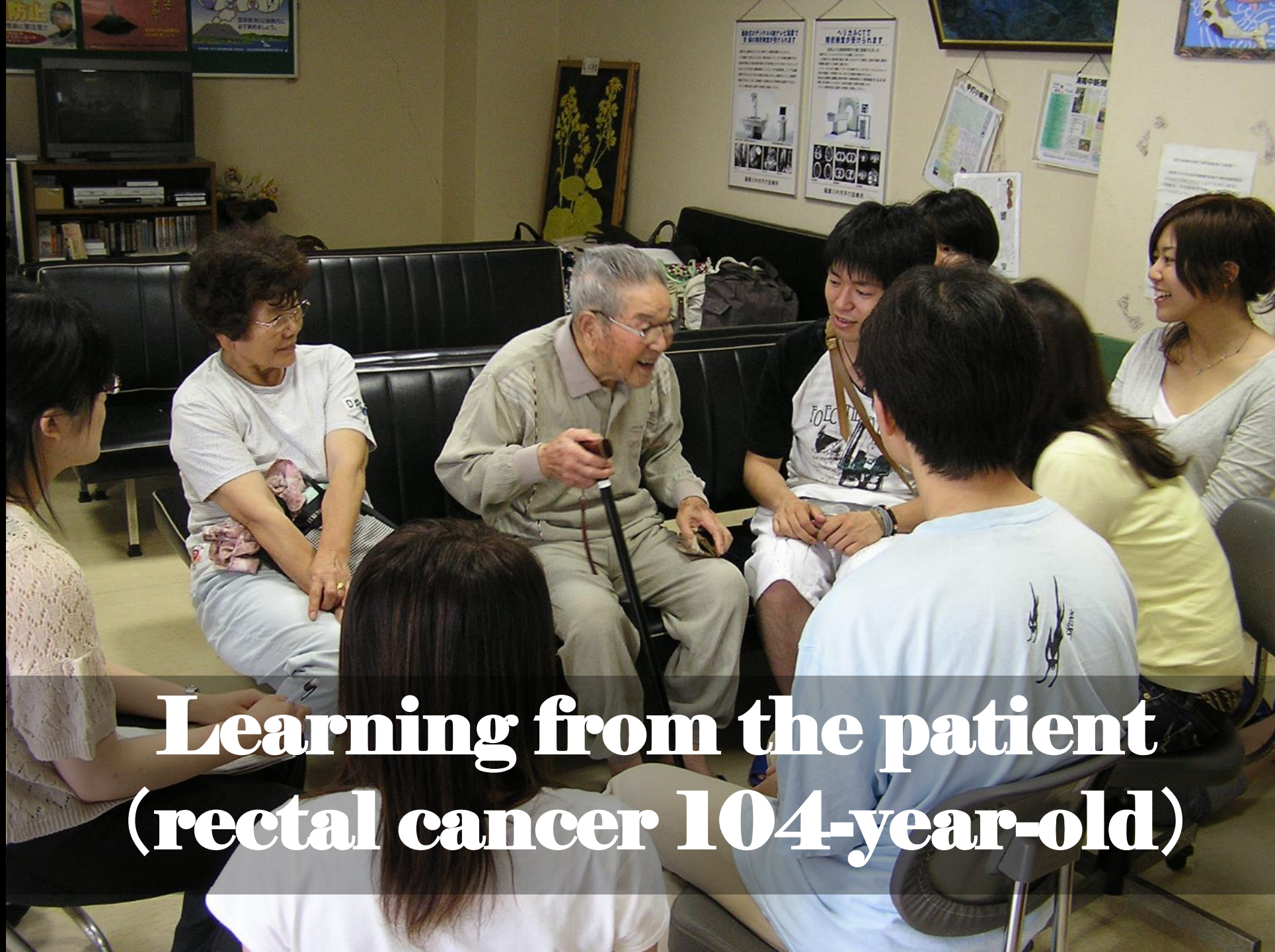





**Home visit**





**Learning from the patient  
(rectal cancer 104-year-old)**



# Island Medicine is a worldwide issue





**I miss those old days** 13,000 to 2,000







**Living on the island means...**



A photograph of a wooden interior ceiling, likely in a cabin or rustic home. The ceiling features dark wood beams and lighter wood planks. A white, rectangular light fixture with a decorative pattern is hanging from the ceiling. The text "House care" is written in a large, white, serif font, and "Health care" is written in a smaller, white, serif font below it. The text is overlaid on the right side of the image.

**“House care”**  
is as important as  
**“Health care”**





**“tobacconist”**

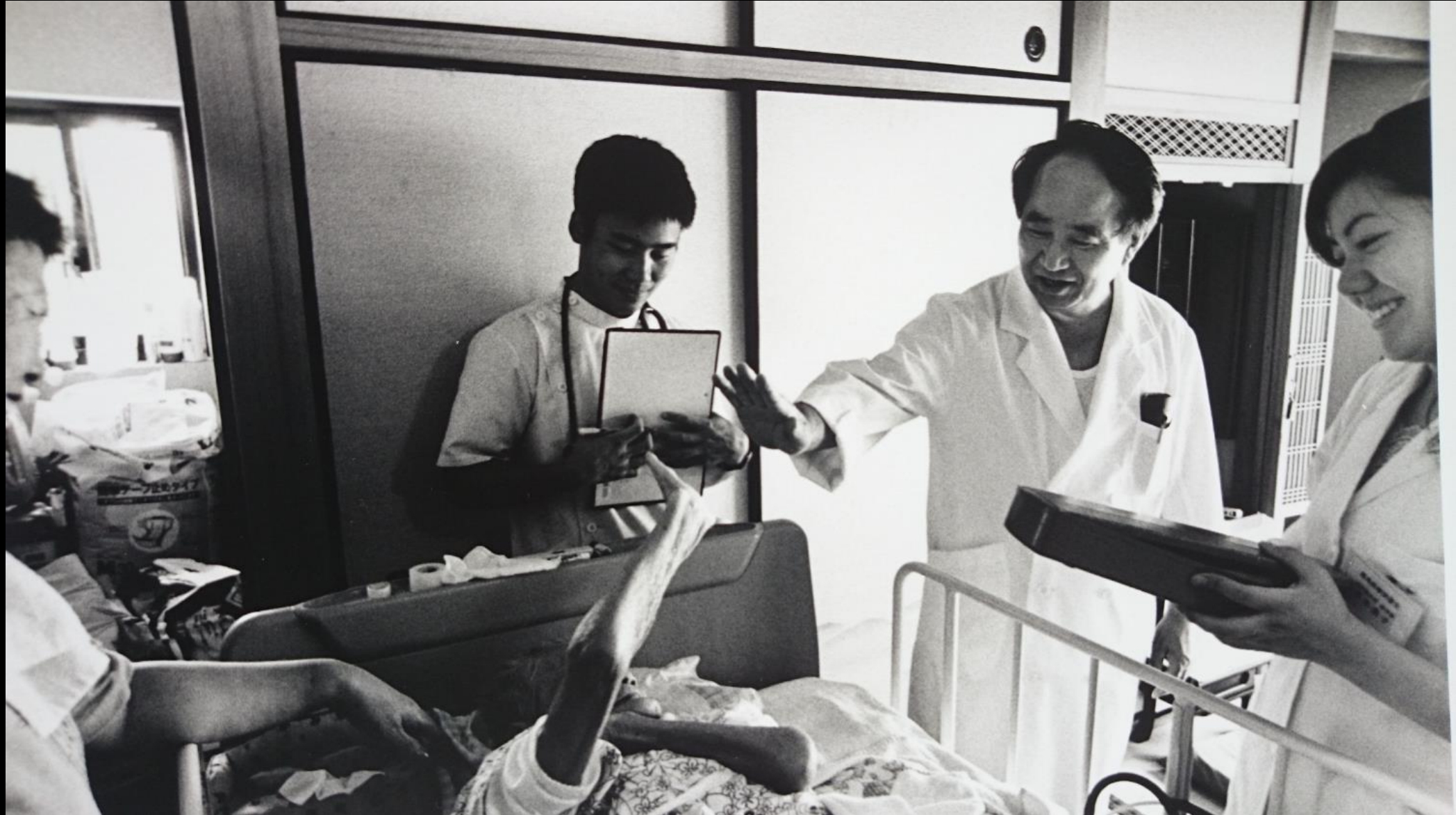**I have 3 customers, use to have 80 people in the village.**



**different favorite...**



# Last touch to say good-bye



# **Last day with villagers**





# Leave island! SAYONARA!







**An Interesting Island Medicine**  
**by Kenjiro Setoue**